



NABL  
MC-3533

## TEST REQUISITION FORM (TRF)



Excellence In Health Care

SPL CODE :

Date :

S.No.	Patient Name in Capital	Age/Sex	Test Code & Test Name	Sample Type	Barcode No.	Sample Collection Date, Time	Ref. Customer	Referral Doctor
1.	Mrs. Nuru khatun	27 f	Double marker DOB - 02/04/1996 LMP - 24/06/2024	Serum	24139969	03/11/24	Sharmaan diagnostic choudhary	Amjara
2.								
3.								
4.			Height - 140g					
5.			Weight - 58 kg					

\* Note Attached Clinical Report If Required

Ccmgmch  
Chandulal Chandrakar Memorial Govt Medical  
College and Hospital, Kachandur Durg, Kachandur,  
Durg, DURG, CHHATTISGARH, 490024  
,DURG,CHHATTISGARH,Pin: 490024



Dr. Anjana Choudhary  
MBBS,MS  
Gynaecology Clinic

Registration No : 20240013202  
No : 11/ Last Visit Date : 20/09/2024 12.00 AM / Token No : 28  
n No : CCMGMCH,,Ground,PAEDIATRIC

OUT PATIENT RECORD (Follow Up)

Name : Mrs. Nuri Khatun  
Sex/Age : 27Y 3M 16D / F  
Department : Obstetrics and Gynaecology  
Dept. Reg. No : 20240001321  
Unit : unit1  
Patient Type : General

Registration Amount : Rs. 0  
Mobile No :

Address : power house, DURG(CHHATTISGARH)  
Date of Registration : 30/09/2024 11.37 AM

MLC Patient : NO

Last Complete Collection Date/Amount : 14/06/2024 09.39 AM/Rs. 0

3.P = 100/70 mm Hg  
wt = 58 kg

R.P.L

3 Abortions  
(midterm, Ineg  
Abs)

26/9/24

N.T. Normal

SL 12.5 wks

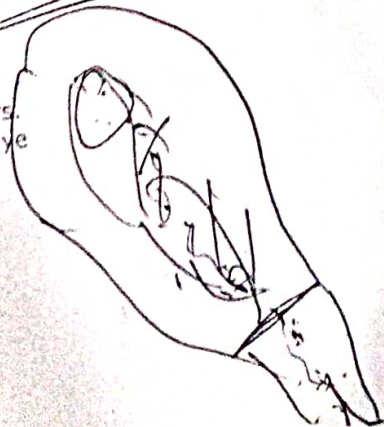
MT. 0.79

MB (M)

BPD 8.4-2025

At  
Dual marks

Prepared By: Mrs.  
Nirmala Gajbhaye



Plan for encirculation  
opth

after Dual marks  
repm

Date Time: 30/09/2024 11.37 AM





# SHRIMAN DIAGNOSTICS

(A UNIT OF SHRIMAN ASSOCIATES)



0788 - 4014135



+91-93011-81903

Pt's Name	NURI KHATUN	Age/Sex	27 Yrs / Female
Ref. Doctor	DR. ANJANA CHOUDHARY	Bill No	PATB25560
Billing Date	27/09/2024	Report Collection Date	27/09/2024

## USG OBS N.T. / N.B. SCAN

- Single live intrauterine foetus with **VARIABLE** Presentation is seen at the time of examination.
- **Liquor:** Liquor Is Adequate In Amount.
- **Placental Location:** Anterior, Grade- II.
- **Cervical length:** 4.1 cms.
- **The Nuchal fold thickness is 0.79 mm. (WNL). The nasal bone is normal and ossified.**
- Foetal movement are identified and foetal heart is positive.
- Routine biophysical profile parameters of the foetus were observed to be adequate.

**Foetal Heart Rates :** 182 B/Min. Regular.

BPD Measures	: 2.02 cm. Corresponds To	: 13 Weeks 2 Day.
HC Measures	: 7.22 cm. Corresponds To	: 13 Weeks 0 Days.
AC Measures	: 6.04 cm. Corresponds To	: 12 Weeks 6 Days.
FL Measures	: 0.74 cm. Corresponds To	: 12 Weeks 2 Days.
CRL Measures	: 5.88 cm. Corresponds To	: 12 Weeks 3 Days.


Average Ultrasound Age Is : 12 Weeks 5 Days.

**Expected Date Of Delivery By Ultrasound** : 06.04.2025

**Expected Date Of Delivery By LMP** : 03.04.2025

DR. SHRIRANJAN RAO  
DMRD, DNB  
Consultant Radiologist





# SHRIMAN DIAGNOSTICS

(A UNIT OF SHRIMAN ASSOCIATES)



0788 - 4014135



+91-93011-81903

Estimated Foetal Weight Is : 60 Gms.  $\pm$  9 Gms.

This scan is not level II scan; this is done only to assess fetal growth parameters fetal weight and fetal wellbeing.

## UTERINE ARTERY DOPPLER:

	PSV	EDV	PI	RI	S/D
RIGHT UTERINE ARTERIES	42.09 cm/s	11.25 cm/s	1.56	0.73	3.74
LEFT UTERINE ARTERIES	27.23 cm/s	12.77 cm/s	0.82	0.53	2.13

## IMPRESSION

**SINGLE LIVE INTRAUTERINE FOETUS WITH VARIABLE PRESENTATION IS SEEN AT THE TIME OF EXAMINATION, WHICH CORRESPONDS, TO GESTATIONAL AGE 12 WEEKS, 5 DAYS.**

**EDD: 06.04.2025.**

**The Nuchal fold thickness is 0.79 mm. (WNL). The nasal bone is normal and ossified.**

**The CRL is 5.88 cm.**

**Disclaimer:** -Please note that USG study has certain limitations !sometimes fetal anomalies may Not get diagnosed due to nature of anomaly, Gestational age, foetal positioning and limitations of machine thence absence of mention of foetal anomaly in study does not always rule out its possibility..(Fetal echo is not included in this scan).

**Declaration:** -I declare that while conducting Ultrasonography/ Image, Scanning on patient, I Have Neither detected nor disclosed the sex of her fetus to anybody in any manner.

DR. SHRIRANJAN RAO  
DMRD, DNB  
Consultant Radiologist