

**IMPRESSION :**

**Single live intrauterine gestation of 12 weeks 4 days.**

**NT scan is normal.**

**Advice - Correlation with serum double markers.**

**Suggest anomaly scan at 18-22 weeks of gestation.**

All congenital anomalies are not detected by sonography and are subject to fetal position and advanced gestational age. All measurements including birth weight are subject to statistical variations.

\* I **MRS NISHA UGALE**, declare that by undergoing ultrasonography/image scanning etc. I do not want to know the sex of my foetus.

Signature of pregnant women \*

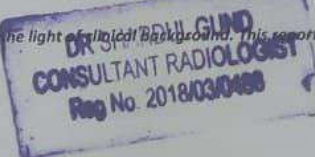
Nisha

I, **DR. SHARDUL GUND**, declare that while conducting ultrasonography/image scanning etc. on **MRS. NISHA UGALE**. I have neither detected nor declared sex of her foetus to anybody in any manner.

Shardul

**DR. SHARDUL GUND**  
**M.B.B.S., MD (RADIO -DIAGNOSIS)**  
**Fetal Medicine foundation certified**  
**(London, UK)**  
**CONSULTANT RADIOLOGIST**

(Note: This is professional opinion, not the final diagnosis & should be interpreted in the light of clinical background. This report is not for medico legal purposes. Always suggest a second opinion if clinically indicated.)



3T MRI | 16 Slice CT Scan | Sonography | 3D/4D | Colour Doppler | 2D Echo | Digital X-Ray  
Pathology | Portable X-Ray | OPG | PFT | ECG

Baner | Kasarwadi | Pimpri | Hinjewadi | Shikrapur | Lonikalbhor | Kharadi | Dhanori | Vishrantwadi | Alandi Charoli | Surat Ved Road  
Surat Amroli | Keshavnagar | Shirwal | Khopoli | Kedgaon Ahmednagar | Wadgaon Maval | Vairag | Wanwadi | Airoli | SUS

• Website : [www.imagesense.in](http://www.imagesense.in) •

### SONOGRAPHY OF GRAVID UTERUS

PATIENT NAME: MRS.NISHA UGALE

AGE/SEX: 25YRS/FEMALE

REF.BY: DR. SAYALI MAR ATHE

DATE: October 3, 2024

.....  
LMP: 09/07/2024

GA BY LMP: 12 weeks 2 days

EDD BY LMP: 15/04/2025

GA BY USG: 12 weeks 4 day

EDD BY USG: 13/04/2025

Single live intrauterine fetus noted with changing lie.

- CRL: 60.7 mm corresponding to 12weeks 4 day.
- Fetal cardiac activity present (FHR= 169 bpm)
- \*Nuchal Translucency measures : 1.1mm ( Normal )
- Nasal bone echo seen.
- Ductus Venous shows normal wave form and PI 0.89
- Placenta developing posterior.
- No e/o subchorionic collection is noted.
- Internal os is closed. Cervical length measures 3.6 cm.
- Right uterine artery PI measures= 1.64
- Left uterine artery PI measures = 2.5
- Mean PI of the uterine arteries = 2.07

3T MRI | 16 Slice CT Scan | Sonography | 3D/4D | Colour Doppler | 2D Echo | Digital X-Ray  
Pathology | Portable X-Ray | OPG | PFT | ECG

Baner | Kasarwadi | Pimpri | Hinjewadi | Shikrapur | Lonikalbhor | Kharadi | Dhanori | Vishrantwadi | Alandi Charoli | Surat Ved Road  
Surat Amroli | Keshavnagar | Shirwal | Khopoli | Kedgaon Ahmednagar | Wadgaon Maval | Vairag | Wanwadi | Airoli | SUS

• Website : [www.imagesense.in](http://www.imagesense.in) •