

PATIENT'S NAME: MR MAHESH CHOUDHARY

AGE / SEX: 26YRS/M

REF BY: DHANASHREE HOSPITAL

DATE: 16/09/2024

MRI RIGHT KNEE JOINT WITH CONTRAST

Technique:

Multiplanar, multiecho MR of the Right knee joint was performed on 3 Tesla machine.

Observations:

Diffuse synovial thickening noted with heterogeneous enhancement on post-contrast imaging. Mild diffuse joint capsular thickening and enhancement noted.

Mild enhancement is seen in the popliteus muscle and in the myotendinous junction.

Multiple subcm to enlarged discrete popliteal lymph nodes are seen; largest measuring 22 x 14 mm.

Multifocal deep bony erosions noted in the periarticular region in the lower femur, upper tibia, and fibula.

Mild knee joint effusion with fluid distending the medial and lateral recess of the suprapatellar bursa. The anterior and posterior cruciate ligaments are normal.

Anterior and posterior horns of the medial and lateral meniscus are normal. The meniscotibial and meniscomfemoral ligaments are normal. The medial and lateral collateral ligaments are normal. The quadriceps tendon and ligamentum patellae appear normal.

Medial patellofemoral ligament and patellar retinaculum appear normal.

Impression:

- **Diffuse synovial thickening noted with heterogeneous enhancement on post-contrast imaging. Mild diffuse joint capsular thickening and enhancement noted.**
- **Mild enhancement is seen in the popliteus muscle and in the myotendinous junction.**
- **Multiple subcm to enlarged discrete popliteal lymph nodes are seen; largest measuring 22 x 14 mm.**

PATIENT'S NAME: MR MAHESH CHOUDHARY

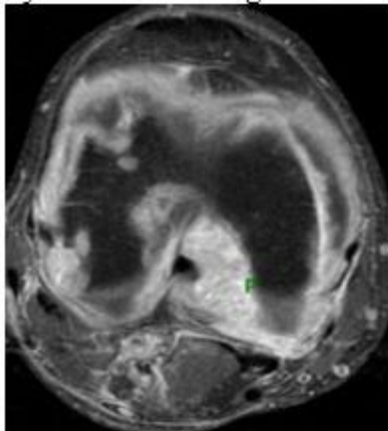
AGE / SEX: 26YRS/M

REF BY: DHANASHREE HOSPITAL

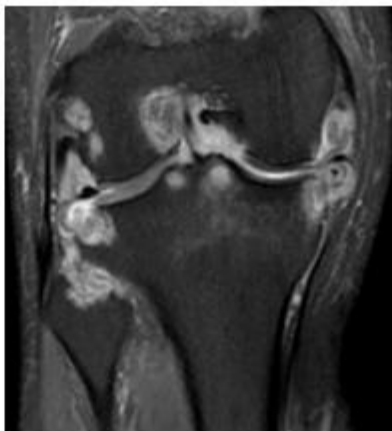DATE:16/09/2024

- **Multifocal deep bony erosions noted in the periarticular region in the lower femur, upper tibia, and fibula.**
Above features are suggestive of infective synovitis. Suggest: Lab correlation.
- **Mild knee joint effusion with suprapatellar bursal effusion.**

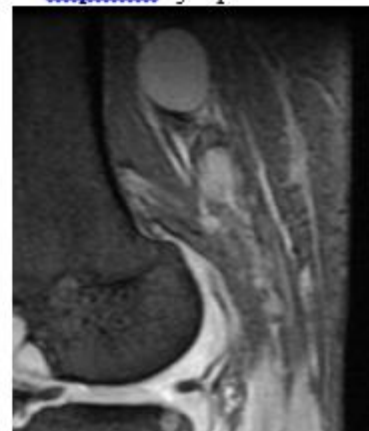
Synovial thickening



Bone erosions



Popliteal lymph nodes



*Thanking you for the referral.
With regards,*

DR. NITESH JAIN
MBBS MD DMRE AFIH

DR DIVYATA HINGWALA
MD, DM (NEURORADIOLOGY)



DR. KETAN KALASKAR
MD RADIODIAGNOSIS

Investigations have their limitation. Solitary pathological/Radiological & other investigations never confirm the final diagnosis. They only help in diagnosing the disease in correlation to clinical symptoms & other related tests. Please examine accordingly.