


Mrs. Laxmi Devi F 
DR. Ujwala Karade } 30

LMP 26/07/2024

DOB 06/06/1994

Child - ~~First~~ No

Weight - 50 kg

Height - 5'1

9691452257

9826044



4D SONOGRAPHY, COLOUR DOPPLER ULTRASOUND AND GENETIC CLINIC

Agrasen Chowk, Magarpara Road, Bilaspur - 495 001 (C.G.) Ph : 07752 - 400616, Mobile : 74403 33999, 88221 18855

Patient name	Mrs. LAXMI DEVI	Age/Sex	30 Years / F
Patient ID	09092425	Visit no	2
Referred by	Dr. UJWALA KARADE, MBBS	Visit date	28/10/2024
LMP date	26/07/2024, LMP EDD: 02/05/2025[13W 3D]		

OB - First Trimester Scan Report (NT Scan)

Indication(s)

10

(CORRECTED LMP FROM FIRST REPORT)

Real time B-mode ultrasonography of gravid uterus done.

Route: Transabdominal

Single intrauterine gestation

Maternal

Cervix measured 3.70 cm in length.

Internal os is closed .

Normal mean uterine artery PI .

Right Uterine	0.44	● — — — — —
Left Uterine	0.48	● — — — — — (<1%)
Mean PI	0.46	● — — — — —

Fetus

Survey

- Placenta : Anterior
Lower end of placenta is reaching the internal os.
- Liquor : Normal - subjective assessment
- Umbilical cord : Two arteries and one vein
- Fetal activity : Fetal activity present
- Cardiac activity : Cardiac activity present .
Fetal heart rate - 159 bpm


E-NATAL SEX
TERMINATION
NOT DONE HERE

ULTRASOUND DIAGNOSIS IS BASED ON APPEARANCE OF GRAY SCALE SHADES, AND IT IS ALSO AFFECTED BY TECHNICAL PITFALLS, HENCE-IT IS SUGGESTED TO CO-RELATE ULTRASOUND OBSERVATION WITH CLINICAL AND OTHER INVESTIGATIVE FINDING TO REACH THE FINAL DIAGNOSIS. NO LEGAL LIABILITY IS ACCEPTED. NOT FOR MEDICO-LEGAL PURPOSE.


खीजा सोनोग्राफी : फोन : 07752 - 400616, मोबाइल : 74403 33909

Mrs. LAXMI DEVI / 09092425 / 28/10/2024 / Visit No 2

Biometry(Hadlock, Unit: mm)

CRL 72.7, 13W 3D  (48%)

Aneuploidy Markers (mm)

Nasal Bone	Present
NT	1.4  (11%) Normal
Ductus Venosus	Normal flow
Tricuspid Regurgitation	No e/o tricuspid regurgitation seen

Fetal Anatomy

Intracranial structures appeared normal

Neck appeared normal.

Spine appeared normal. No evidence of significant open neural tube defect

Fetal face appeared normal

Two inflows and two outflows tract noted .

Abdominal situs appeared normal

Bladder appeared normal.

All four limbs are visualized.

Impression

SINGLE ALIVE INTRAUTERINE GESTATION CORRESPONDING TO A
GESTATIONAL AGE OF 13 WEEKS 3 DAYS.

GESTATIONAL AGE ASSIGNED AS PER LMP

PLACENTA - ANTERIOR

LOWER END OF PLACENTA IS REACHING THE INTERNAL OS.

LIQUOR - NORMAL - SUBJECTIVE ASSESSMENT

NORMAL MEAN UTERINE ARTERY PI.

SUGGESTED -

- 1 - NIPS / DOUBLE MARKER TEST .
- 2 - FOLLOW UP USG AT 19 - 22 WKS FOR ANOMALY SCAN .

Thanks for reference.

All anomalies cannot be detected in ultrasound due to certain technical limitations, obesity ,
certain fetal positions , fetal movements or abnormal amount of amniotic fluid .

All information given today is as per the findings on scan today
but does not guarantee normality

of all fetal organs (structurally and functionally) in future .

Also note that ultrasound permits assessment of fetal structural anatomy

but not the function of these structures.

All measurement including estimated fetal weight are subject to statistical variations

I, Dr. Mrs. Riya Lalit Makhija, declare that while conducting USG of Mrs. LAXMI , W/o- Mr. MANESH ,
I have neither detected nor disclosed the sex of her fetus to anybody in any manner.

DR.MRS. RIYA LALIT MAKHIJA

First trimester screening for Downs
Maternal age risk 1 in 870

Fetus	Risk estimate - NT	Risk estimate - NT + NB
A	1 in 5118	1 in 17059



UNITY HOSPITAL



UHID : 6451

Name : LAXMI DEVI

Age : 28 Yrs Sex : Female

Mobile : 7440940639

Address : KHOTRI, PENDRA

OPD No. : OPD22-23/15366

Date : 28/10/2024 01:29:00 No. 1

Consultant : DR. UJWALA KARADE MBBS, DGO, DI

Ref. By : SELF

Chief Complaints & H/O :

G, E 13 wks preg
H/O Thyroidectomy

LMP - 22/7/24

EDM - 29/04/25

Physical Examination

SPO2 : 97%

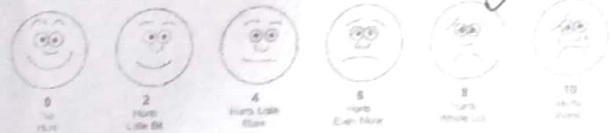Pulse : 81 bpm

BP : 100/60 mmHg

Temp : 98°F

WT : 50 kg

RBS : 9.6 mg/dl



Allergies :

None

- ① Tab Folvite (5) OD x 1 month
- ② Tab Ezorb D3 OD x 1 month
- ③ Tab Fe daily OD x 1 month
- ④ Syrup Glucolac 200mg Bix 7 days

Examination :

Ins

- CBC
- Visceral markers
- Thyroid profile
- ~~Do~~ Triphasic markers
- Blood glucose

(Std) ⑤ Cap Sustan SR 600mg x 15 days

⑥ Tab Thyronorm maint 40 Pri 75
Set and San lavng

+91 89596 44885
unityhospital12@gmail.com

Brilliant Public School Campus,
Mission Hospital Road, Bilaspur (C.G.) 495 001