



समर्पण

इमेजिंग (सोनोग्राफी) सेंटर, बारशी
Diagnosis with Care and Excellence

डॉ. मनोज बी. जाधव

MBBS(JJH), MD (RAD), DNB, MNAMS, DICR, EDiR
FFM (Fellowship in Fetal Medicine), Bangalore
Ex. Senior Resident Sion Hospital, Mumbai
Ex. Clinical Associate, Apollo Hospital, Navi Mumbai
Consultant Radiologist
Fetomaternal Imaging Consultant
FMF Certified (11-13 wks Scan)



PATIENT NAME	: MRS. AMRUTA GANESH PURI	AGE/SEX	: 25 Years/ F
REF. BY	: DR. SADEKAR SHIVAJI, MBBS, MS (OB/GY)	DATE	: 30-Oct-24

OB-First Trimester Scan Report

LMP: 01-Aug-24	GA (LMP): 12 weeks 6 days	EDD (LMP): 08-May-25
----------------	---------------------------	----------------------

Real time B-mode ultrasonography of gravid uterus done.

Route: Transabdominal

Maternal:

Cervix measured 3.54 cm in length. OS closed.

Right uterine PI : 2.22

Left uterine PI : 1.31

Mean PI : 1.77 (65 %)

Fetus Survey

: Single intrauterine gestation.

Placenta : Posterior wall.

Liquor : Normal.

Umbilical cord : Three vessel cord seen.

Fetal activity : Fetal activity present.

Cardiac activity : Cardiac activity present. Fetal heart rate-161 bpm

Biometry (Headlock)

	Measurement	GA	Percentile	
BPD	2.03 cm	13 weeks 2 days	45.80 %	
HC	7.94 cm	13 weeks 3 days	46.20 %	
AC	6.25 cm	13 weeks 0 days	64.50 %	
FL	0.87 cm	12 weeks 4 days	31.10 %	
EFW	65 Gms	12 weeks 3 days	26.10 %	

CRL- 6.52 cm. (12 weeks 6 days) IT (Intracranial translucency) - 0.20 cm

Aneuploidy Markers

Nasal Bone : 0.16 cm -Present

Nuchal translucency : 0.14 cm -Normal.

Ductus venosus : No "a" wave reversal.

Tricuspid regurgitation : No tricuspid regurgitation seen.

Fetal anatomy:

Head : Skull/brain appears normal. Intracranial structures appear normal.

Neck : Neck appears normal.

Spine : Spine appears normal.

Face : PMT and orbits seen.

Thorax : Thorax appears normal.

Heart : Four chamber and outflow tracts appear normal.

Abdomen : Stomach bubble appears normal. Cord insertion seen.

KUB : Bladder appears normal. Kidneys could not be evaluated at present.

Extremities : Both upper limbs and lower limbs seen.

P.T.O

Dr. Manoj B. Jadhav

Reg. No. 2013/07/2596

Shop No. 5, Near Nikita Hotel, Kurduwadi Road, Barshi - 413401. For Appointment : 74986 48919, 784090 8919

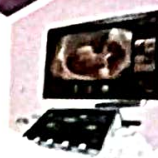

समर्पण

इमेजिंग (सोनोग्राफी) सेंटर, बारशी
Diagnosis with Care and Excellence

डॉ. मनोज बी. जाधव

MBBS(JJH), MD (RAD), DNB, MNAMS, DICR, EDiR
FFM (Fellowship in Fetal Medicine), Bangalore
Ex. Senior Resident Sion Hospital, Mumbai
Ex. Clinical Associate, Apollo Hospital, Navi Mumbai
Consultant Radiologist
Fetomaternal Imaging Consultant
FMF Certified (11-13 wks Scan)



PATIENT NAME	:	MRS. AMRUTA GANESH PURI	AGE/SEX	:	25 Years/ F
REF. BY	:	DR. SADEKAR SHIVAJI, MBBS, MS (OB/GY)	DATE	:	30-Oct-24

IMPRESSION:

- Single live intrauterine gestation corresponding to gestational age of 12 weeks 6 days.
- Menstrual age is 12 weeks 6 days.
- EDD by USG (Biometry-CRL): 08-May-25
- Assigned EDD (As per LMP): 08-May-25
- Nuchal translucency (0.14 cm), nasal bone, tricuspid regurgitation: within normal limits.
- Endocervical length: 3.54 cm: Normal however it will be best assessed after 14 weeks.
- Uterine artery screen negative for PET.
- No obvious sonological structural abnormalities detected for this gestation.

COMMENTS:

First Trimester Screening for Trisomies:

	Risk From History Only	Risk From History Plus NT, FHR
Trisomy 21:	909	5000
Trisomy 18:	2000	10000
Trisomy 13:	10000	10000

SUGGEST:

- 1) Double marker test today.
- 2) TIFFA (level II) scan between 18-20 weeks.

Thanks for the reference,
With regards.

Please Note: All abnormalities and genetic syndromes cannot be ruled out by ultrasound examination. Ultrasound examination has its own limitations. Some abnormalities evolve as the gestation advances. The pickup rate of abnormality depends on gestational age of the fetus, fetal position, tissue penetration of sound waves, and patient's body habitus.

Disclaimer: I Dr. Manoj Jadhav declare that while conducting ultrasonography/image scanning on this patient, have neither detected nor disclosed the sex of her fetus to anybody in any manner.

Best Wishes,
For Appointments Please Contact: 7498648919/7840908919.

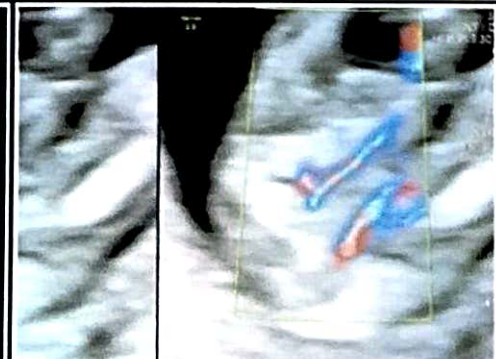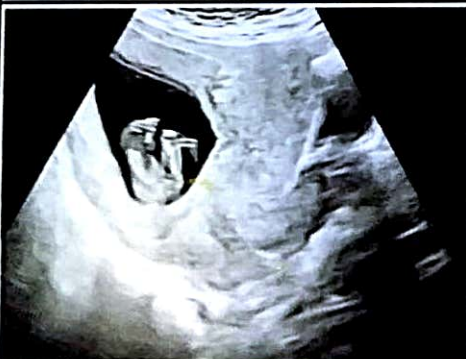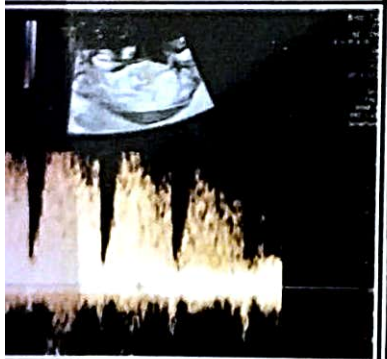
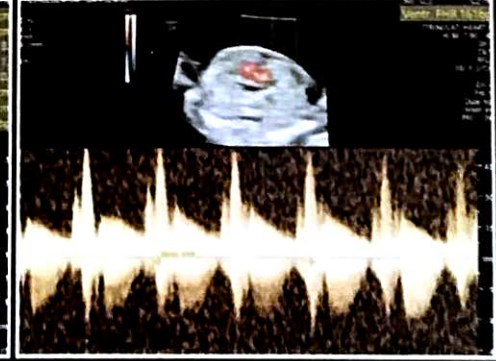
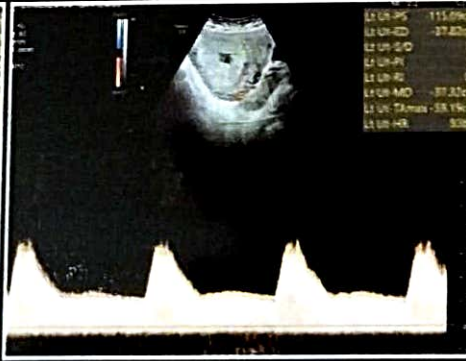
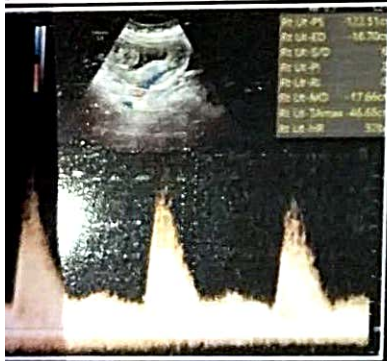
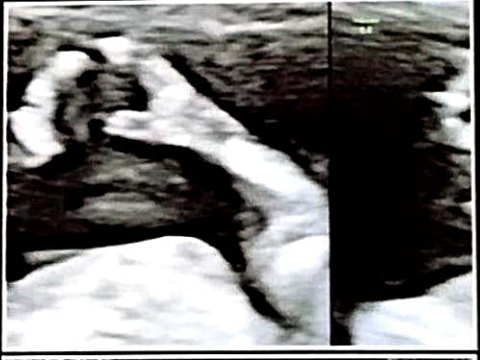
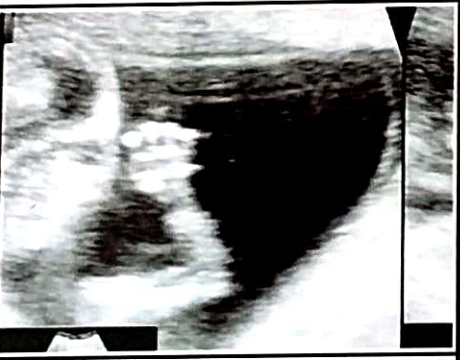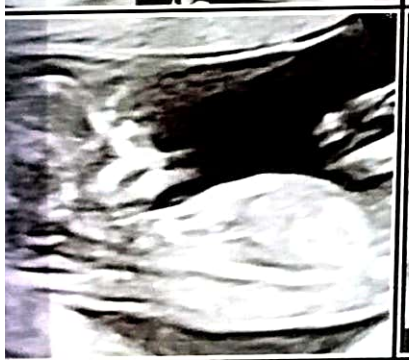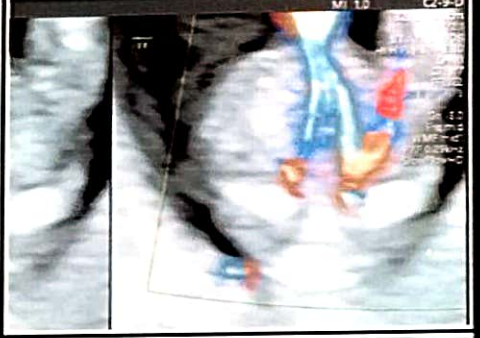
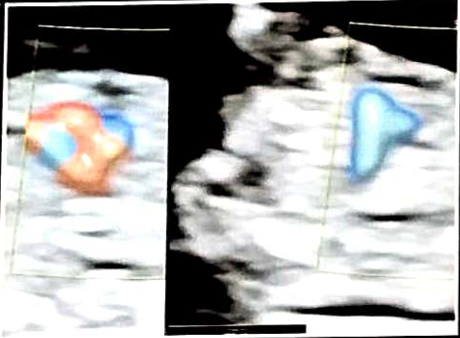
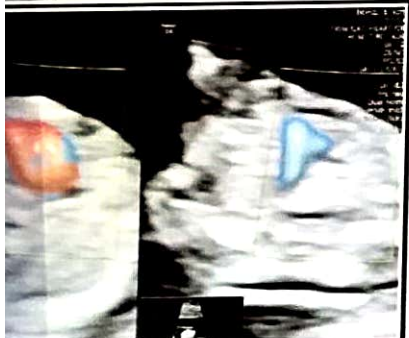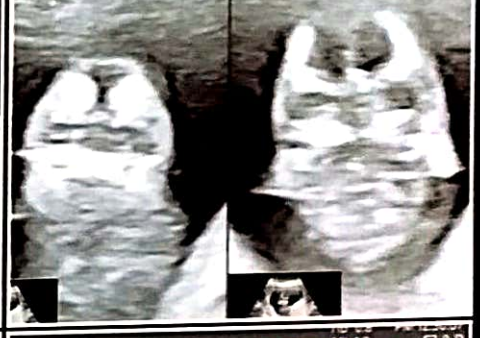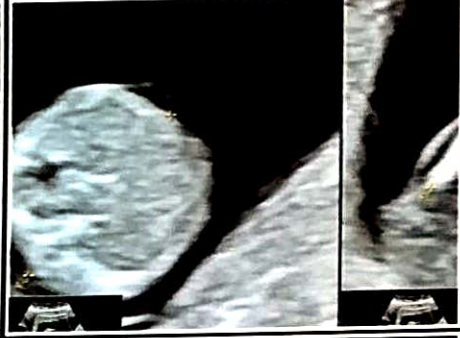
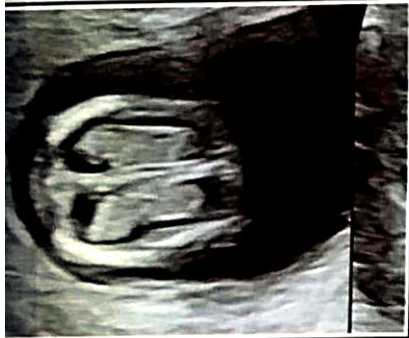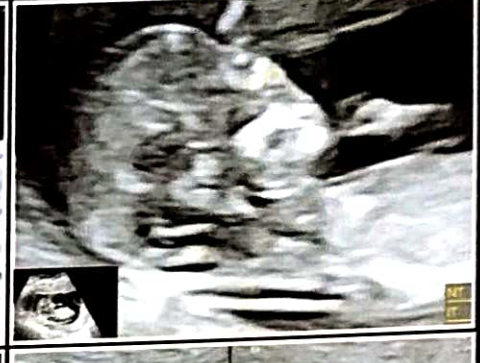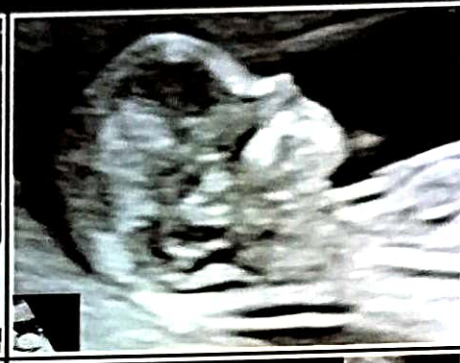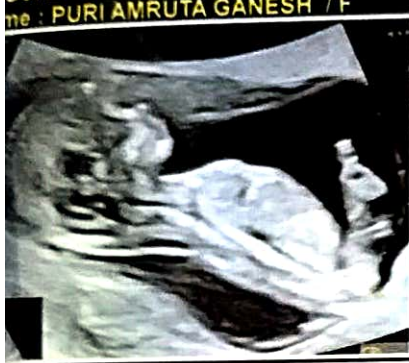Dr. Manoj B. Jadhav

Reg. No. 2013/07/596

SAMARPAN DIAGNOSTIC CENTER, BARSHI

Ref. by : SADEKAR^SHIVAJI
Done by : MANOJ^B.^JADHAV

Oct 2024
me : PURI AMRUTA GANESH / F



Ammeter pun' / F1 25

UMP - 1 Aug 2024

BOB - 18 Oct 1999

Hight → 5-3 Froh

Weight - 80 kg

Bup: - 1 W / 80