

# ASHAVI CLINIC

**Dr. Prerna Thapa**  
 MBBS, CGO, DMCH  
 Fellowship in OBS/Gynae  
 Medical Officer  
 Indian Red Cross Society  
 Bhopal



**Clinic :**  
 Shop No. 5, Fortune Estate  
 Kolar Road, Bhopal (M.P.)  
 Mob.: 9425012122  
 Timing : 7 pm - 9:30 pm  
 (Sunday Closed)

R

Mrs Marshallini  
 26y

Date 16/10/24

Prim  
 mul-ly

Del-17 Aug

Amz

2mth.

PIA W An

4sky

USG →  
6 wky

Lab Emmytal-D

- - - - 4202 ✓

Delayed  
 by 15 days

Bt 2/10/60

2e ceakey + 202

2e meylai 2pas 43dy

Ad  
 415 gm

ASORLT<sup>y</sup> w

sy 2eyapan  
 2sdaily  
 111

doni

- HSD

- HBSA

- TSH

- UDRLT<sup>y</sup> w

sy 2002 4118 ei many

Lab Embunat SR 420 dy

2nd 1/9/24

2nd 1/0  
PAWAD

Gr 4  
12/11/24

R

Lab Cheerful + 20dy

- a -

Lab Babyfala 4 20

- o - a -

Lab Enbonatsk 4 20

Sy 2y cups  
1/2 day 4 1st

---

Aek

us 4  
M1/MB  
scan to  
se 4  
tallai cebery

29/11/24

Refer to Dr Ankun

The County Hospital

Aek  
Dental marker  
in pie

~



Patient Name: MRS HARSHALINI SUNERI	Date: 29/11/2024
Patient Id: 35194	Age/Sex: 28 Years / FEMALE
Ref Phy: DR. PRERNA THAPA MBBS DGO,	Contact No:

**Examination : Obstetric USG of First Trimester Scan Report (Level -1)**

Dating	LMP	GA		EDD
		Weeks	Days	
By LMP	LMP: 01/09/2024	12	5	08/06/2025
By USG		13	3	03/06/2025

AGREED DATING IS (BASED ON Biometry)

Single live intrauterine gestation	
OBSTETRIC USG STUDY	
Fetus	: Single
Fetal Movement	: Adequate
FCA	: 158/ bpm
Liquor	: Normal
Placenta	: RT lateral

Biometry (Headlock)	
CRL	71.5 mm      13weeks 3 days
CERVIX	Is 40 mm in length with closed os & canal.

Aneuploidy markers :			
Nuchal Translucency	1.2 mm	Normal	12%
Both Nasal Bones	1.5 mm	Normal	
Umbilical cord	Single Umbilical artery Seen		
Tricuspid flow	Mid-systolic Tricuspid Regurgitation (TR ) with PSV: 85 cm/sec.		
Ductus venosus	Normal continues forward flows.		

Fetal anatomy :	
Head :	shape & size normal , Neck: normal , Spine: normal, Choroid plexus , Cerebral peduncles ,intracraniallucency , AD normal.
Face:	Orbits, lenses, PMT, mandible gap sign normal.
Thorax:	Lung parenchyma , CT ratio , diaphragm normal.
Abdomen :	Normal ant. Abdominal wall & cord insertion , stomach ,





**Extremities & Fetal spine :**

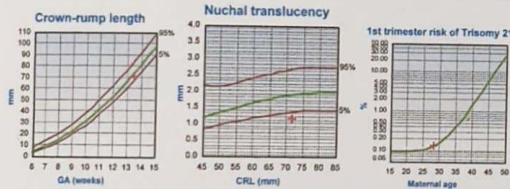
Both upper & lower limbs are normal. Hands, feet seen. Normal.

Vessels	S/D	RI	PI	PI Percentile	Remarks
Right Uterine Artery	4.3	0.77	1.76	67.8%	No early Diastolic notch seen
Left Uterine Artery	4.2	0.76	1.75	67.1%	No early Diastolic notch seen
Mean Uterine Artery			1.75	67.8%	
Ductus venosus	4.9	0.8	1.13		PSV=45.1 Normal waveform Pattern

**Impression :-** Single live Intrauterine gestation corresponding to a gestational age of 13 Wks 3 days Gestational age assigned as per biometry ( CRL )

- Single Umbilical artery Seen.
- Mid-systolic Tricuspid Regurgitation (TR) with PSV: 85 cm/sec.
- There is an suspicion of Fusion of Bilateral lower pole of both Kidneys, Horseshoe kidney.

**ADV: Double marker correlation**  
Followup scan at 16 weeks.



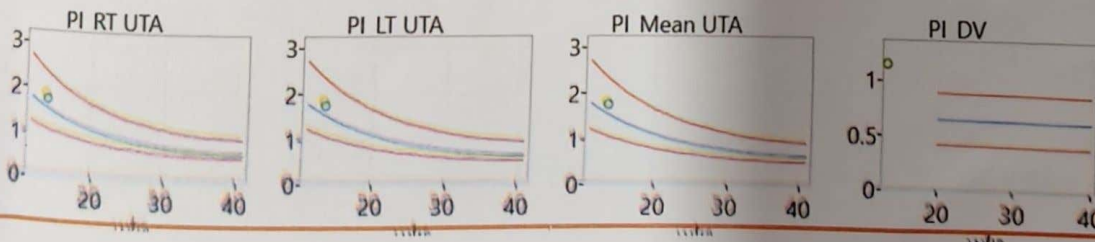
Please note that all anomalies can not be detected all the times due to various technical and circumstantial reasons like gestation period, fetal position, quantity of liquor etc. The present study can not completely confirm presence or absence of any or all the congenital anomalies in the fetus which may be detected on post natal period. Growth parameters mentioned herein are based on International Data and may vary from Indian standards. Date of delivery (at 40 weeks) is calculated as per the present sonographic growth of fetus and may not correspond with period of gestation by L.M.P. or by actual date of delivery. As with any other diagnostic modality, the present study should be correlated with clinical features for proper management. Except in cases of Fetal Demise or Missed Abortion, sonography at 20-22 weeks should always be advised for better fetal evaluation and also for base line study for future reference.

Declaration of Doctor/Person conducting ultrasonography/image scanning

I, DR SONAM VERMA declare that while conducting sonography on MRS HARSHALINI SUNERI, I have neither detected nor disclosed the sex of the fetus to anybody in any manner.

**DR SUPRIYA MAHESHWARI**  
MD, RADIOLOGY  
CONSULTANT RADIOLOGIST  
Reg No : 11111

*Sonam*  
**DR SONAM VERMA**  
FETAL MEDICINE SPECIALIST MD,  
RADIOLOGY  
CONSULTANT RADIOLOGIST  
Reg No : 18797

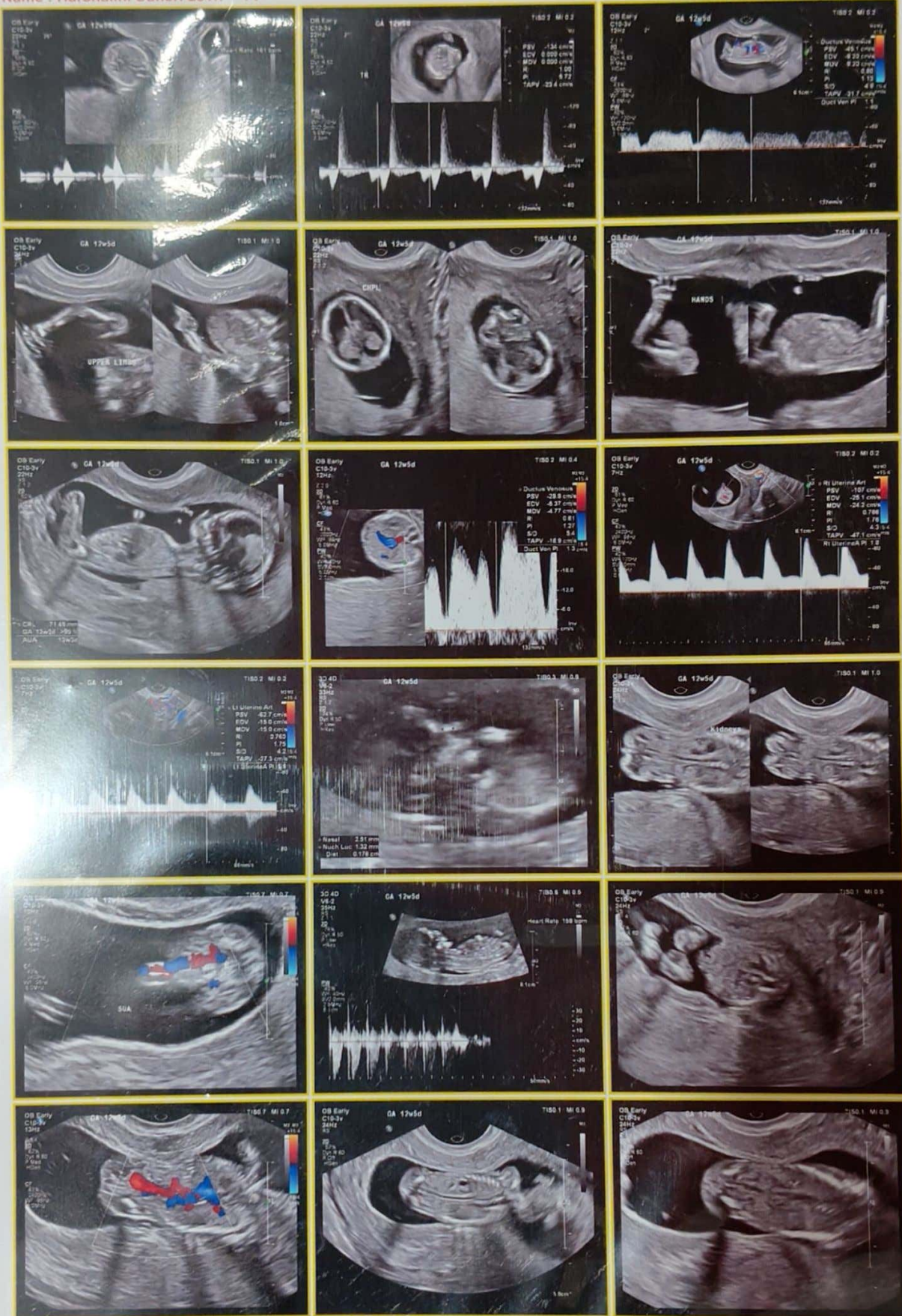

www.dr.supriyamaheshwari.com

# DR SUPRIYA MAHESHWARI ULTRASOUND & MAMMOGRAPHY CENTER

Name : Harshalini Suneri 28Y/F / F

29 Nov 2024 Study : Free Form



Handwritten signature/initials.



# DR SUPRIYA MAHESHWARI ULTRASOUND & MAMMOGRAPHY CENTER

Name : HARSHALINI SUNERI 28Y/F / F Study : Free Form 14 Oct 2024

