



AURANGABAD DIAGNOSTIC CENTER

• Sonography • Fetal Radiology
• Colour Doppler
• Anomaly Scan • 3D/4D
• Fetal Echo
• Digital X-rays & Procedures
TIMING : 9.00 AM to 9.00 PM Monday To Saturday

Patient name	Mrs. RANI KACHOLE	Age/Sex	20 Years / Female
Patient ID	VSX200479-25-02-01-16	Visit no	1
Referred by	Dr. SHAMLEE SARODE	Visit date	01/02/2025
LMP date	05/11/2024, LMP EDD: 12/08/2025(12W 4D) C-EDD: 13/08/2025(12W 3D)		

OB - First Trimester Scan Report

Real time B-mode ultrasonography of gravid uterus done.

Route: Transabdominal
Single intrauterine gestation

Maternal

Cervix measured 3.80 cm in length
INTERNAL OS CLOSE

Right Uterine	0.74	—●— (2%)
Left Uterine	1.5	—●— (39%)
Mean PI	1.12	—●— (8%)

Fetus

Survey

PLACENTA- FORMING POSTERIOR

Liquor - Normal

Fetal activity present

Cardiac activity present

Fetal heart rate - 162 bpm

Biometry(Hadlock, Unit: mm)

CRL	61.8, 12W 3D	—●— (50%)
BPD	19.5, 12W 4D	—●— (57%)
HC	70, 12W 1D	—●— (39%)
AC	61, 13W 1D	—●— (69%)
FL	8.8, 12W 3D	—●— (51%)

Aneuploidy Markers

Nasal Bone : SEEN

Nuchal translucency : 1.2 mm NORMAL

Ductus venosus : Normal flow

Tricuspid regurgitation : NO TR.

Fetal Anatomy

Foetal head, limb buds, pulsatile heart, stomach bubble, orbits, NB, PMT, DV seen.

Impression

Intrauterine gestation corresponding to a gestational age of 12 Weeks 3 Days

Gestational age assigned as per biometry (CRL)

Menstrual age 12 Weeks 4 Days

Corrected EDD 13-08-2025

Liquor - Normal

Advice- Follow up anomaly scan evaluation and double marker test correlation

Disclaimer - I declare that while conducting the USG on patient I have neither detected nor disclosed the sex of fetus in any way.

Dr. Amit K. Ingle
Consultant Radiologist

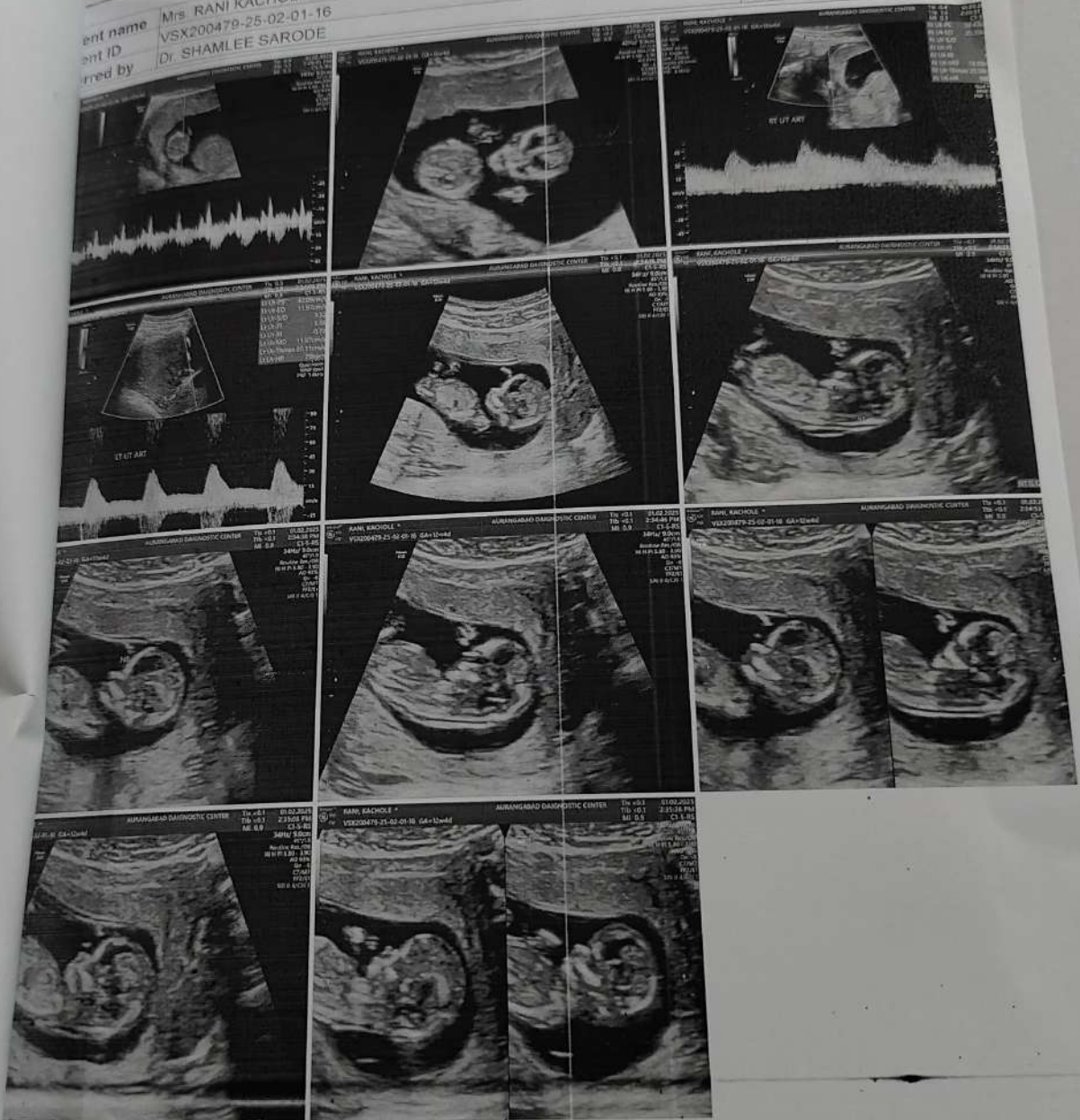
Dr. Neha R. Madle
Consultant Radiologist

Dr. Anup G. Chawade
Consultant Radiologist

Police Well Fare Complex, Beside Police Petrol Pump, MGM-TV Center Road, N-10 CIDCO,
Chatrapati Sambhajinagar (Aurangabad) . Ph. : 0240-2951501 / 2382255 / 9730556587

Patient name Mrs. RANI KACHOLE
 Patient ID VSX200479-25-02-01-16
 Performed by Dr. SHAMLEE SARODE

Age/Sex 20 Years / Female
 Visit no 1
 Visit date 01/02/2025



**DECLARATION OF THE PERSON UNDERGOING
PERNATAL DIAGNOSTIC TEST/PROCEDURE**

Declare that by undergoing

Diagnostic Test / Procedure, I do not want to know the sex of my foetus.
Signature/Thumb impression of the person undergoing
The Prenatal Diagnostic Test/Procedure.

In case of thumb impression

Age : _____ Sex : _____
Address/contact No.: _____

Signature of a person attesting thumb impression

Scanned by (Name)
Date (if any)

Declaration of Doctor

declare that while conduction ultrasonography/
I have neither detected nor disclosed the sex of her foetus to

Scanning on Mrs
in any manner.
Place: Aurangabad

☐ Dr. Anup G. Chalwade
Reg. No. 2005/08/3325

☐ Dr. Amit K. Ingle
Reg. No. 2005/03/2030

☐ Dr. Neha R. Madle
Reg. No. 2012/11/3157

Male ☒ Female ☐

गरोदर मातेचे (गर्भवती स्त्रीचे) शपथपत्र

28/8/25

शपथपूर्वक जाहिर करते की, सोनोग्राफी / इमेज स्कॅनिंग /
ना मला माझ्या गर्भाचे लिंग जाणून घ्यावयाचे नाही.

गर्भवती स्त्रीची सही / अंगठा

अंगठा देणाऱ्या स्त्रीयांसाठी

मा ओळखणाऱ्या व्यक्तीचे नांव : _____ वय : _____ लिंग : _____

मा / दुधवनी क्र. : _____

नांक : / /

सही

डॉक्टरचे/सोनोग्राफी/इमेज स्कॅनिंग करणाऱ्या व्यक्तीचे शपथपत्र
डॉ. नेहा मादले

असे शपथपूर्वक जाहिर करतो की,

मी सोनोग्राफी / इमेज स्कॅनिंग / करतांना मी / आम्ही, गर्भाच्या लिंगाचे निदान केलेले नाही. तसेच गर्भवती मातेला अथवा इतर
व्यक्तीला कुठल्याही पद्धतीने सांगितलेले नाही.

नांक : 1/2/2025

डॉ. अनुप जी चलावदे
रजि. नं. 2004/06/3324

डॉ. अमित के. इंगळे
रजि. नं. 2004/03/2030

डॉ. नेहा आर. मादले
रजि. नं. 2012/11/3157

vivo V29

Sagar k patil Feb 1, 2025, 19:36

- 1) This investigation has been done as per advice of referring doctor. The report is meant to assist referring doctor to have an idea of disease process, if any and is to be correlated with clinical and lab parameters.
- 2) Images cast by sonography & X-ray depend on various shadows produced by both normal and abnormal structures. Shadows of many diseases can look alike, hence there are many limitations in interpretation of the shadows. The reports is professional opinion. It indicates only one of the various possibilities which is to be confirmed/ruled out with further investigations as required.
- 3) For antenatal scanning: All congenital anomalies can not be detected by ultrasound. Interpretation depends upon various factors like foetal presentation, foetal age, amount of liquor, etc. Some anomalies may go undetected. Routine anomaly scan does not include dedicated fetal echocardiography.
- 4) All measurements are subject to statistical variation.
- 5) I declare that, while conducting the USG on patient. I have neither detected or disclosed the sex of fetus in any way.

or. The report is meant to assist
 to be correlated with clinical and
 produced by both normal and
 experience there are many
 professional opinion. It indicates
 ed out with further
 ed by ultrasound
 a, foetal age, amount of
 can does not include
 ected or disclosed the sex

