



# ASHIRWAD DIAGNOSTIC CENTRE

SONOGRAPHY • 3D - 4D • COLOUR DOPPLER • 2 D - ECHO • DIGITAL X- RAY

Kohinoor Majestic, 1st Floor, Above Suman Super Market,  
Behind Kundan Hyundai Showroom, Near Thermax Chowk, Chinchwad, Pune 411 019.

Ph. No.: 7722093930 / 9960406686

Timings : Mon to Sat - 9 am to 8:30 pm.

DR. HARSHAD ADIK MD-Radio(Mum)

DR. ASHISH ADSULE MD-Radio(Mum), FRCR (UK)

DATE : 14 FEB 2025

NAME : MRS. MORE PRATIKSHA

REF. BY : DR. MALEKAR S. S.

## USG PELVIS (TAS & TVS):

Urinary bladder appears normal, shows clear contents.

Uterus is normal in size and reveals no obvious focal lesion.

Uterine size is 68 x 45 x 35 mms.

Endometrial echo is in midline and shows few blood clots. Endometrial thickness is 4 mms.

There is no evidence of intra or extrauterine pregnancy or obvious retained products of conception at present.

Both ovaries appear normal. No significant cystic change is seen.

No parametrial or adnexal mass is seen.

No free fluid or collection is seen in pelvis.

## CONCLUSION:

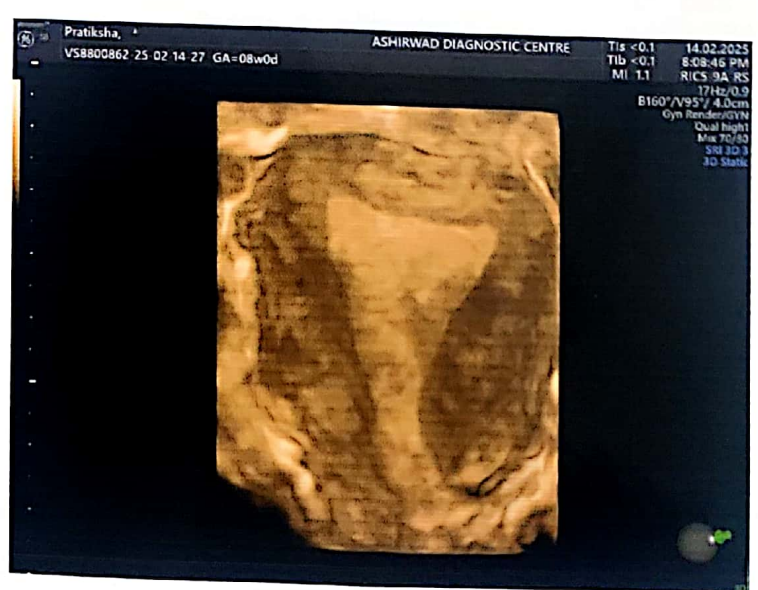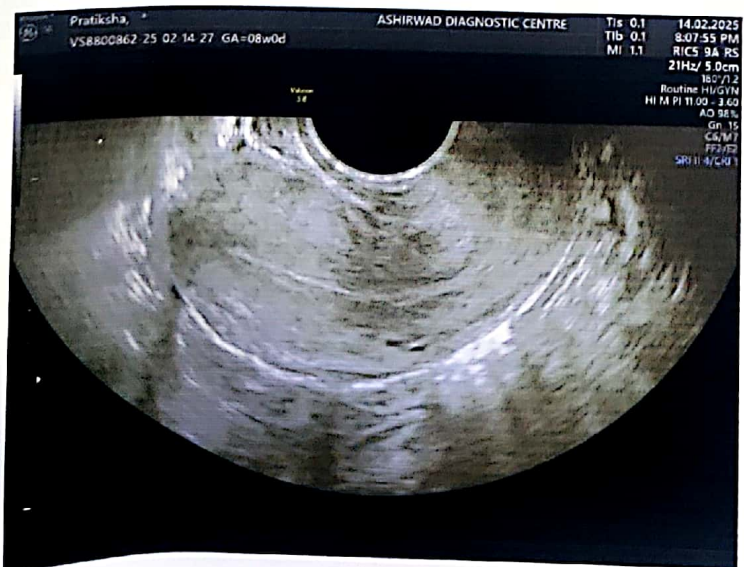
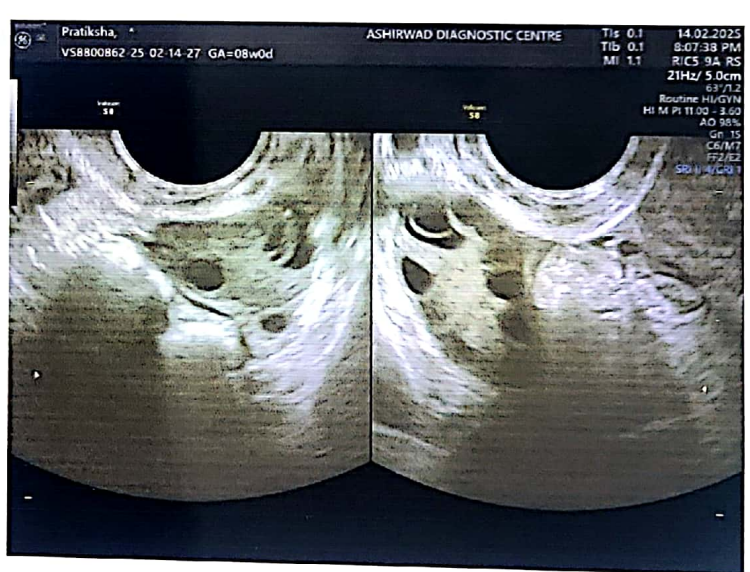
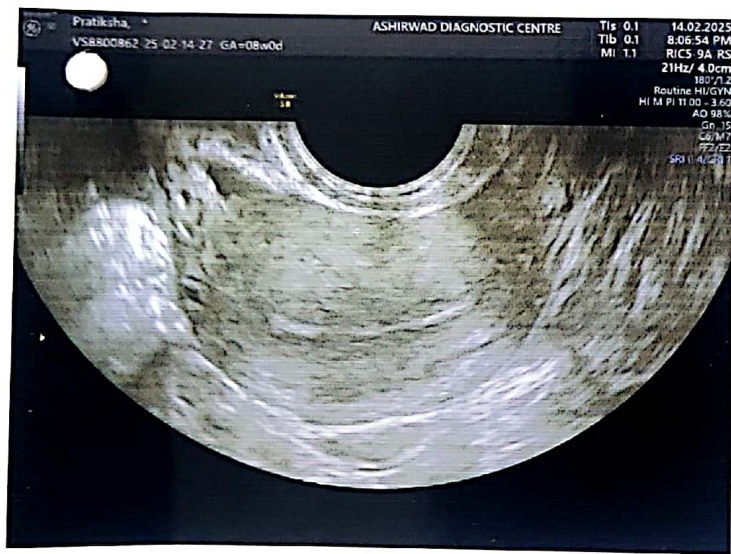
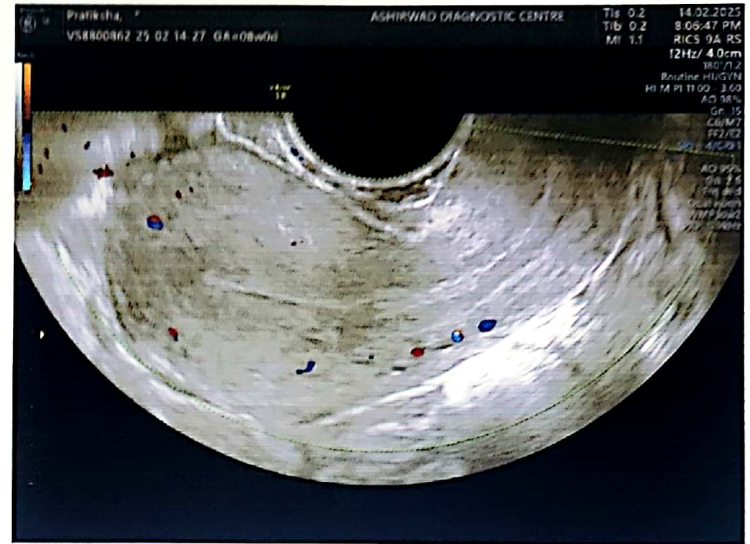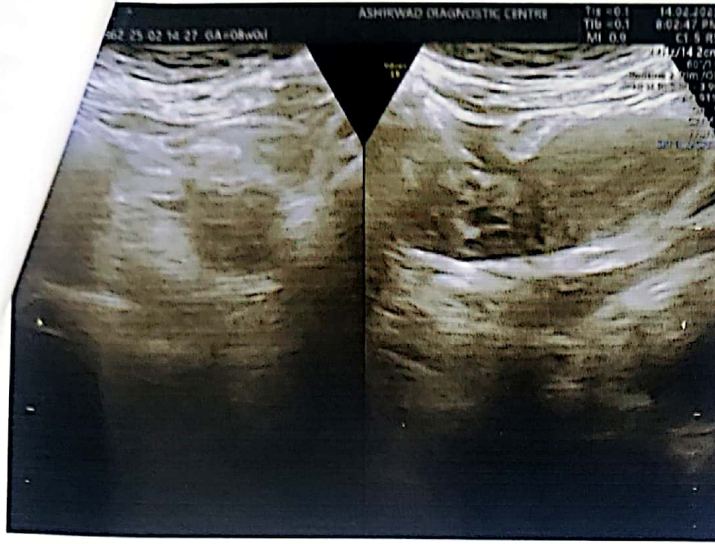
- No evidence of intra or extrauterine pregnancy or obvious retained products of conception at present.
- No abnormality is noted in this study.

Many thanks for the reference,

DR. ASHISH ADSULE

MD Radio-Diagnosis, FRCR (London)







**SHREE HOSPITAL AND POLYCLINIC**

RAMDASNAGAR, CHIKHALI, PUNE 411 062. PH. 9881161969 Reg.No.313

Date : 14.2.25

Mrs. Pratiksha MoreAdv.Obs. Vgt.(L.M.P. 20.12.24)For :-

✓ Viability / GA

✓ / Sonology Scan

Fetal well being

Liquor / BPP

PV bleeding / leaking

Dr. Mrs. Mafekar S. S.

Dr. Mrs. Mafekar S. S.

(BfMS, PGDYT)

Reg. No. 22309

No Substitute Please

वरील औषधे मिळण्याचे विश्वसनीय ठिकाण

**श्री मेडीकल अँड जनरल स्टोअर्स**

मो. नं. : 7720907778



# ASHIRWAD DIAGNOSTIC CENTRE

SONOGRAPHY • 3D - 4D • COLOUR DOPPLER • 2 D - ECHO • DIGITAL X- RAY

Kohlnoor Majestic, 1st Floor, Above Suman Super Market,  
Behind Kundan Hyundai Showroom, Near Thermax Chowk, Chinchwad, Pune 411 019.

Ph. No.: 7722093930 / 9960406686

Timings : Mon to Sat - 9 am to 8:30 pm.

DR. HARSHAD ADIK MD-Radio(Mum)

DR. ASHISH ADSULE MD-Radio(Mum), FRCR (UK)

DATE : 08 FEB 2025  
NAME : MRS. MORE PRATIKSHA  
REF. BY : DR. MALEKAR S. S.

## USG OBSTETRIC

L.M.P: 20/12/2024

Period of amenorrhea: 7 weeks, 1 day.

Uterus is gravid.

A single intrauterine gestational sac is seen.

Sac margins are smooth with good decidual reaction.

No separation of the gestational sac or any subchorionic hematoma is seen at present.

Fetal pole is not seen inside the gestational sac.

Yolk sac is not seen.

Mean gestational sac size is 4 mms corresponding to: 5 weeks, 1 day.

Both ovaries appear normal.

No parametrial or adnexal mass is seen.

No free fluid or collection is seen in pelvis.

## CONCLUSION:

- Single smooth intrauterine gestational sac corresponding to 5 weeks, 1 day.

Suggest: Follow up USG after 2 weeks to confirm viability.

Many thanks for the reference,

Dr. Harshad Adik (MD Radio-Diagnosis)

(I declare that during the examination, I have neither detected nor disclosed the sex of the foetus to any body in any manner.  
Not all anomalies can be detected on sonography depending upon various factor like gestational age, fetal position, amount of liquor  
maternal abdominal wall thickness, patient co-operation etc.)

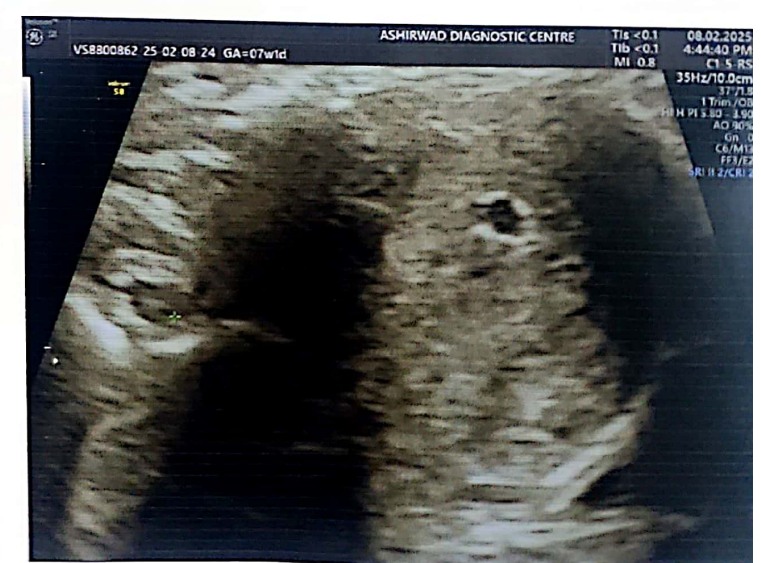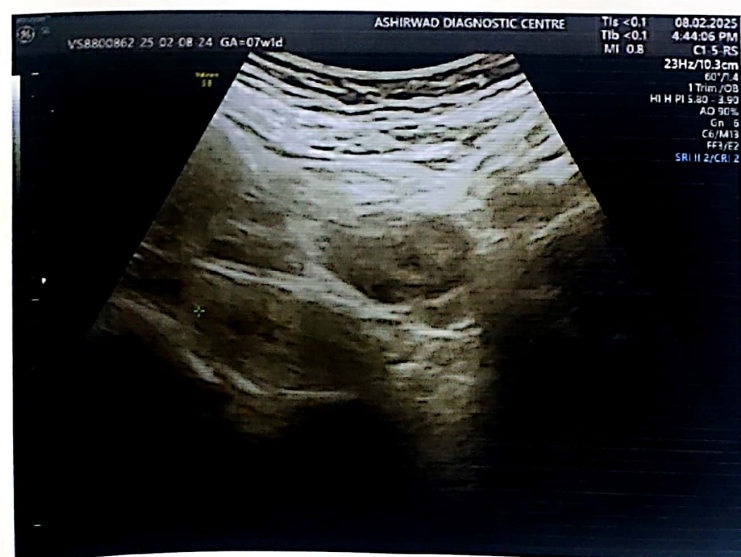
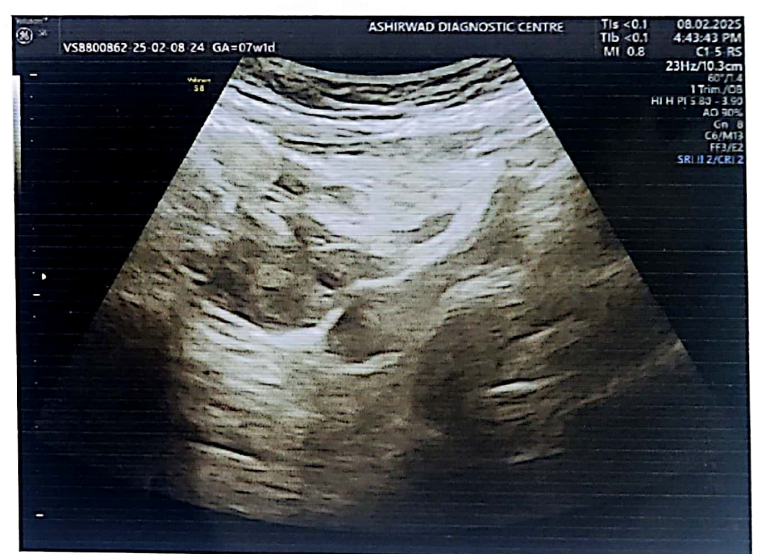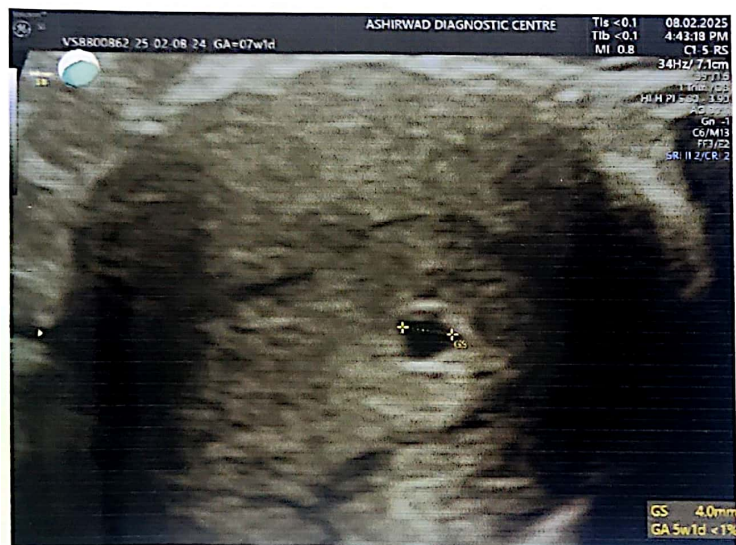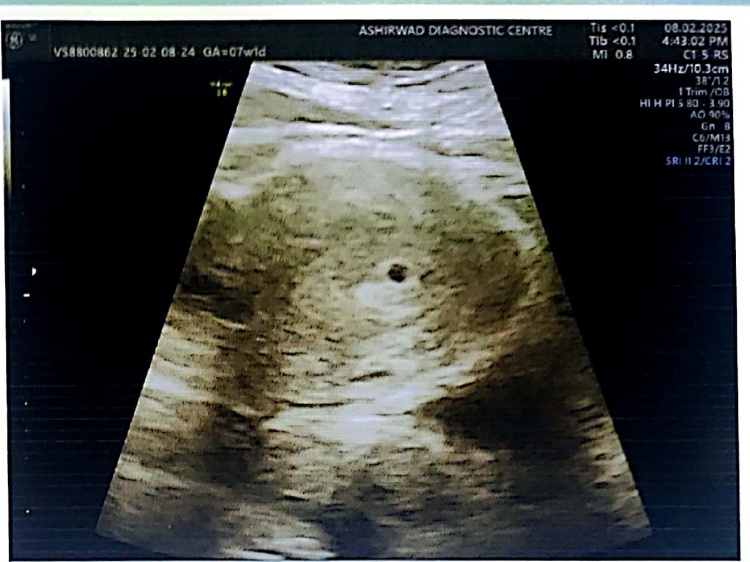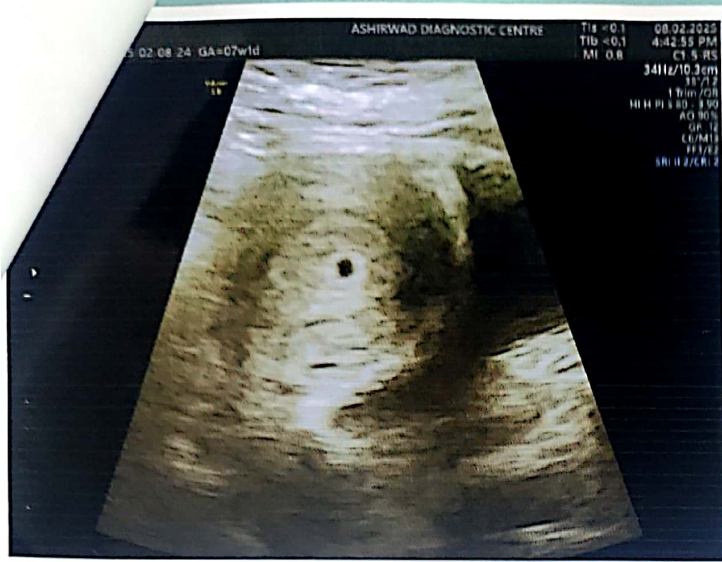I declare that by undergoing ultrasonography / image scanning etc. I do not want to know the sex of my foetus.  
माझी करण्यात येणारी सोनोग्राफी ही गर्भलिंग निदानासाठी नाही याची मला जाणीव आहे. यासाठी मी स्वेच्छेने संमती देत आहे.

Signature / Thumb impression of pregnant women



Scanned with OKEN Scanner






# Ashirwad Diagnostic Centre

## Declaration of pregnant woman

NAME OF PATIENT: MRS. MORE PRATIKSHA

Declare that by undergoing ultrasonography/image scanning etc. I do not want to know to sex of my foetus.



Signature/Thumb impression of pregnant woman

## Declaration of doctor

DR. HARSHAD ADIK

Declare that while undergoing ultrasonography/image scanning on patient,

NAME OF PATIENT: MRS. MORE PRATIKSHA

I have neither detected nor disclosed the sex of her foetus to anybody in any manner.



Signature of the person conducting Ultrasonography/image scanning/director or owner of genetic clinic/ultrasound clinic/image centre.





Patient Name: Pratiksha More	Age/sex: 24 Yr/F
Referred by: Dr. S.S. Malekar	Date: 07/05/2024

**USG PELVIS**

**Suboptimal scan due to empty urinary bladder, TVS not done due to heavy PV bleeding**

Uterus is anteverted, normal in size and shape. It measures 9.6 x 5.1 x 5.2 cms

Myometrium shows normal echotexture. No focal lesion is noted.

**Endometrial echo is thickened. ET measures 24 mm.**

**No intra/extra uterine gestational sac is seen at present scan. No obvious RPOC is seen**

**Blood clots are seen in endometrial cavity.**

Both ovaries appear normal in size, shape and echotexture.

Right ovary measures – 3.2 x 1.4 cm

Left ovary measures – 3.1 x 2.0 cm

No solid or cystic adnexal mass is noted on either side.

No free fluid is seen in pelvis

**IMPRESSION :**

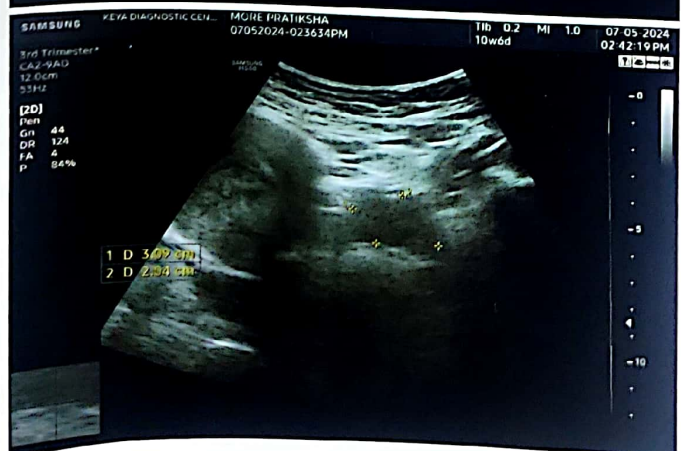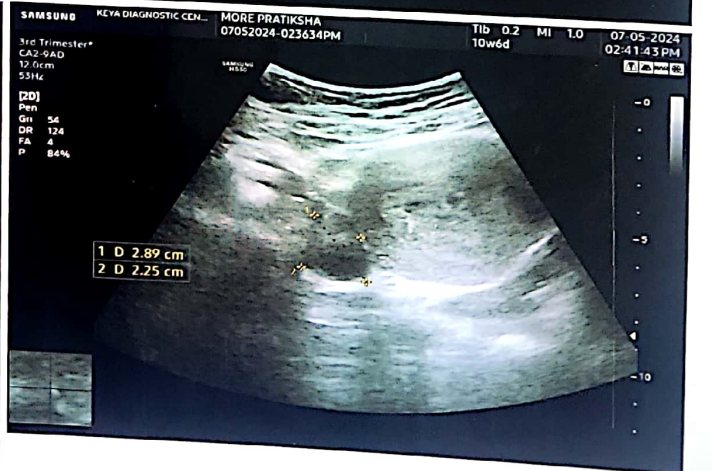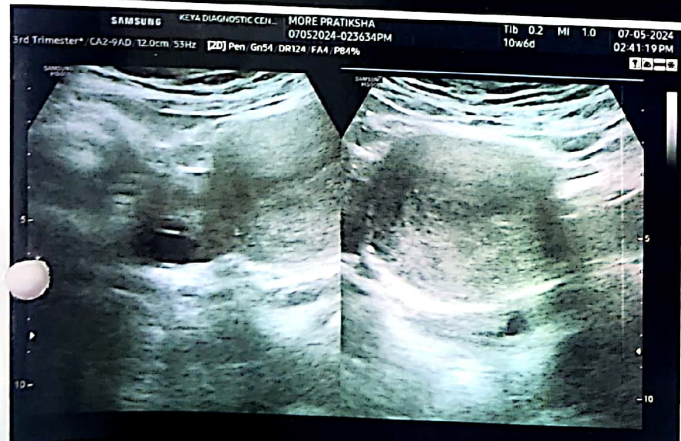
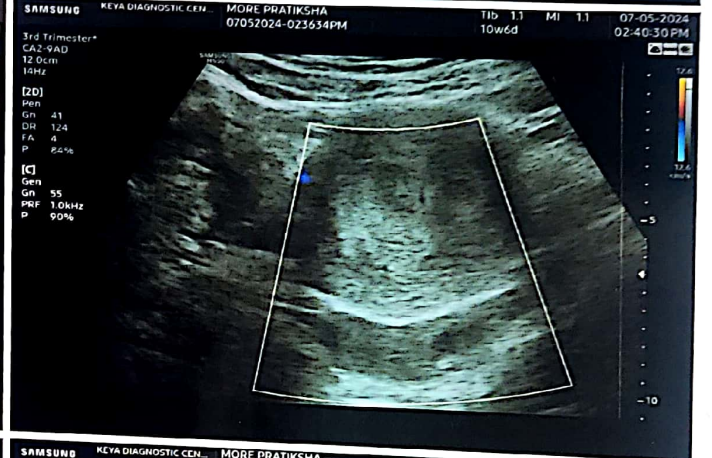
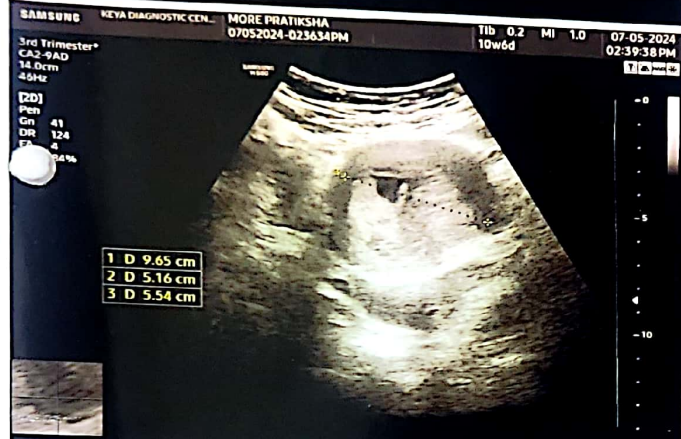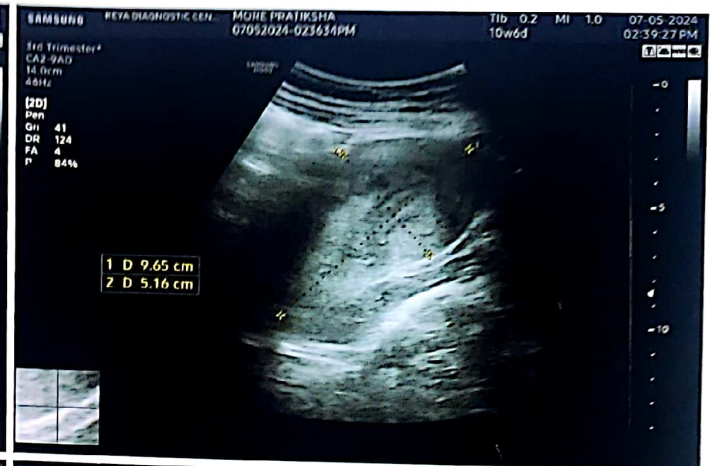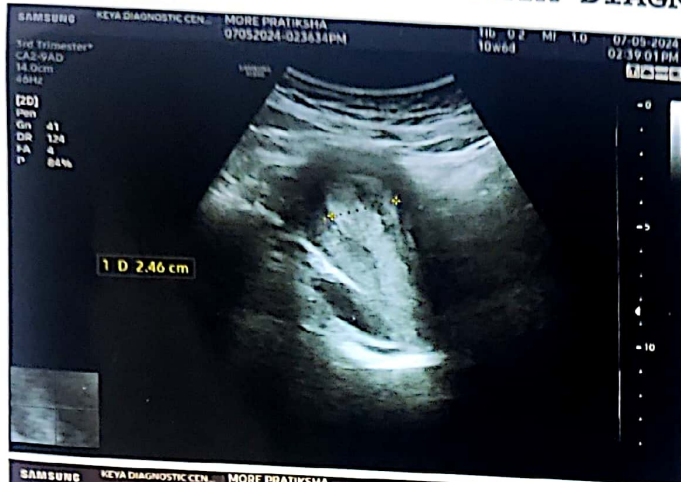- **Thickened endometrium with blood clots within.**
- **No intra/extra uterine gestational sac is seen at present scan. No obvious RPOC is seen**

Adv – Beta HCG level correlation and Follow up scan with TVS

DR. NITIN JADHAV  
MBBS, DMRD, DNB.  
KEM Hosp Mumbai

Typed by AB









# KAMAT HOSPITAL

Department of Ultra Sonography & Colour Doppler

NAME: MRS. PRATIKSHA MORE	AGE: 23	YRS.	DATE: 03/04/24
REF BY: DR. D S KAMAT MD DGO FICOG FICA	PRN NO: 24/0457		
LMP :- 10/02/24 GA :- 7 WEEKS, 4 DAYS	EDD BY LMP :- 16/11/24		

## USG PELVIS:

Uterus is gravid.

A single intrauterine gestational sac is seen.

Sac margins are smooth with good decidual reaction.

No separation of the gestational sac or any sub chorionic hematoma is seen at present.

A single fetal pole and yolk sac are seen inside the gestational sac.

Fetal cardiac activity is seen. (FHR: 101 /bpm)

CRL is 3.5 mms corresponding to: 6 weeks. (D - 7W 4D)

Liquor is adequate.

Internal OS is closed.

Both ovaries appear normal.

No parametrial or adnexal mass is seen.

No free fluid or collection is seen in pelvis.

## CONCLUSION:

Single live intrauterine pregnancy corresponding to 6 weeks.


EDD BY USG :- 27/11/24

Suggest: Follow up USG for Nuchal translucency at 11 to 13 weeks.

DR. YOGESH KAMBLE  
DMRD DNB

**DECLARATION OF PREGNANT WOMAN**I, Mrs. ☒ PRATIKSHA ABHISHEK MORE

असे घोषित करते की अल्ट्रा-सोनोग्राफी/प्रतिमा स्कॅनिंग करून मी माझ्या गर्भाचे लिंग जाणून घेऊ इच्छित नाही. /declare that by undergoing ultrasonography/image scanning etc. I do not want to know the sex of my foetus.



गरोदर स्त्रीची सही/अंगठ्याचा ठसा./Signature/Thumb impression of pregnant woman

**DECLARATION OF DOCTOR**I, Dr. YOGESH R KAMBLE  
patient☒ declare that while undergoing ultrasonography/image scanning onMrs. ☒ PRATIKSHA ABHISHEK MORE

I have neither detected nor disclosed the sex of her foetus to anybody in any manner.



Signature of the person conducting Ultrasonography/Image scanning/Director or owner of genetic clinic/ ultrasound clinic/imaging centre.

**Dr. Yogesh Kamble**

DMRD DNB

(Reg. No. 2005/03/01419)





# KAMAT HOSPITAL

Chapekar Chowk, Chinchwad, Pune - 411 033.

## PREGNANCY PROFILE

DB 16/4/2000

This is a comprehensive list of investigations advised during pregnancy in order to satisfy our selves about the normalcy.

Name of the Patient : Poojilekha Abhishek More Age 24 Yrs.

L. M.P. : 20/2/24 EDD by LMP : \_\_\_\_\_ by USG : 27/11/24

### Visits

1st Trimester ( upto 12 weeks ) every week or as advised

2 nd Trimester ( upto 28 weeks ) every fortnight or month

3 rd Trimester ( 36 weeks ) every week

Injection TT 1st : \_\_\_\_\_ 2nd : \_\_\_\_\_

### Plan of Investigations:

#### • First visit (1st Trimester)

- Blood Group
- Heamogram with platelet count - SOS anemia profile (Hb/indices/Sr Ferritin/TBC/Sr Transferrin) and Hb electrophoresis
- Urine Routine
- BSL - Fasting - SOS Glycosylated Haemoglobin
- HIV / HbsAg / VDRL / HCV
- TSH
  - SOS FT4
  - SOS FT3
  - SOS Anti-TPO
- Baseline Sonography

#### • 11 - 13 Weeks

- Sonography for fetal nuchal translucency and "Double Marker Test" 16/05/24 - 9.00 Am NT

#### • 15 - 17 Weeks

- Quadruple "Triple Marker Test" - screening for Down's Syndrome 14/06/24 - 9.00 Am OHS

#### • 18 - 20 Weeks

- USG - Anomaly Scan

#### • 24 - 28 Weeks

- Repeat USG for Fetal Cardiac Anomalies

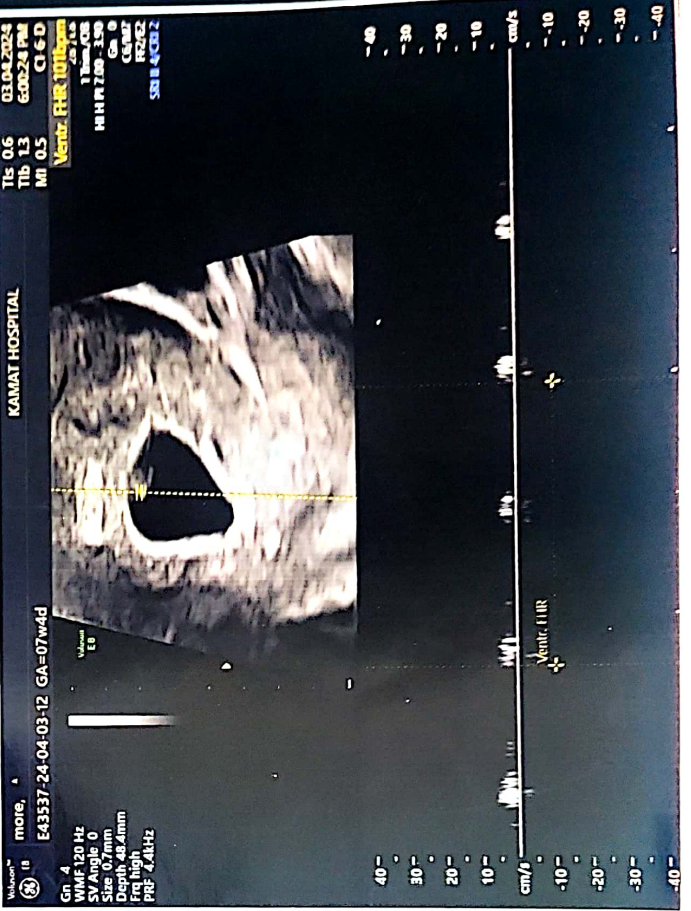
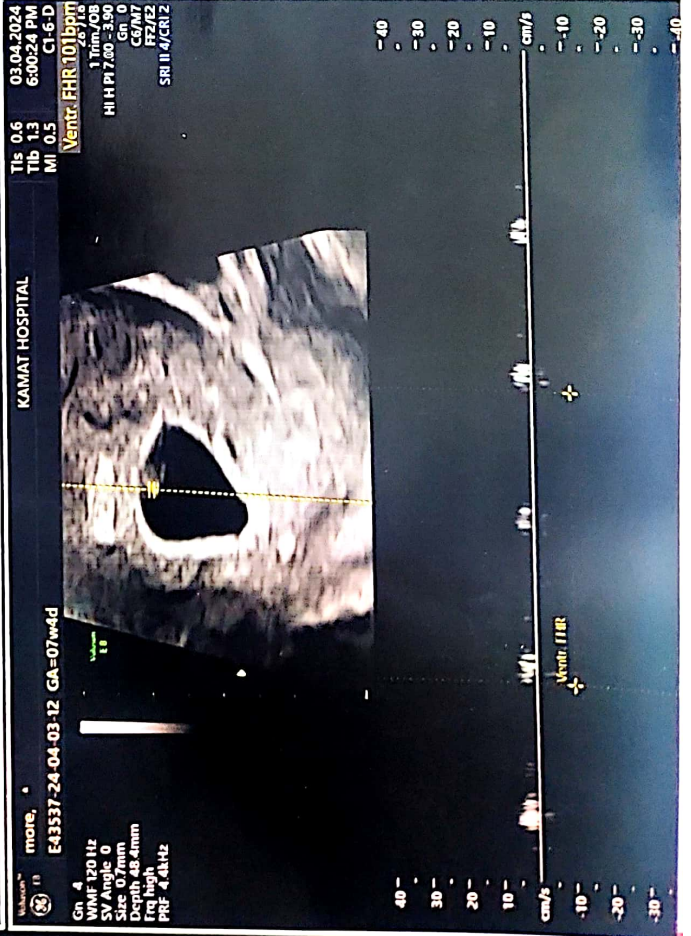
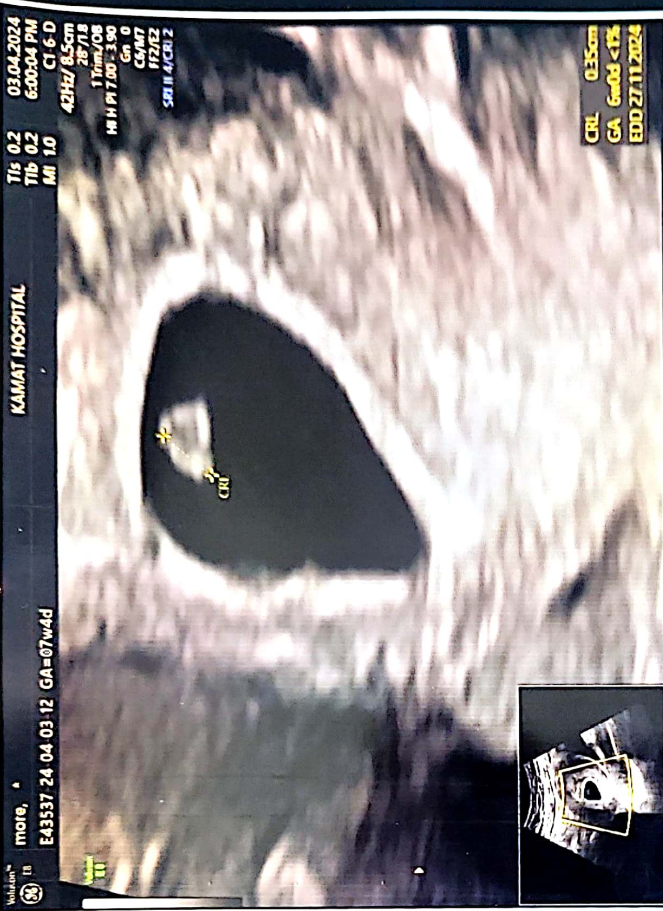
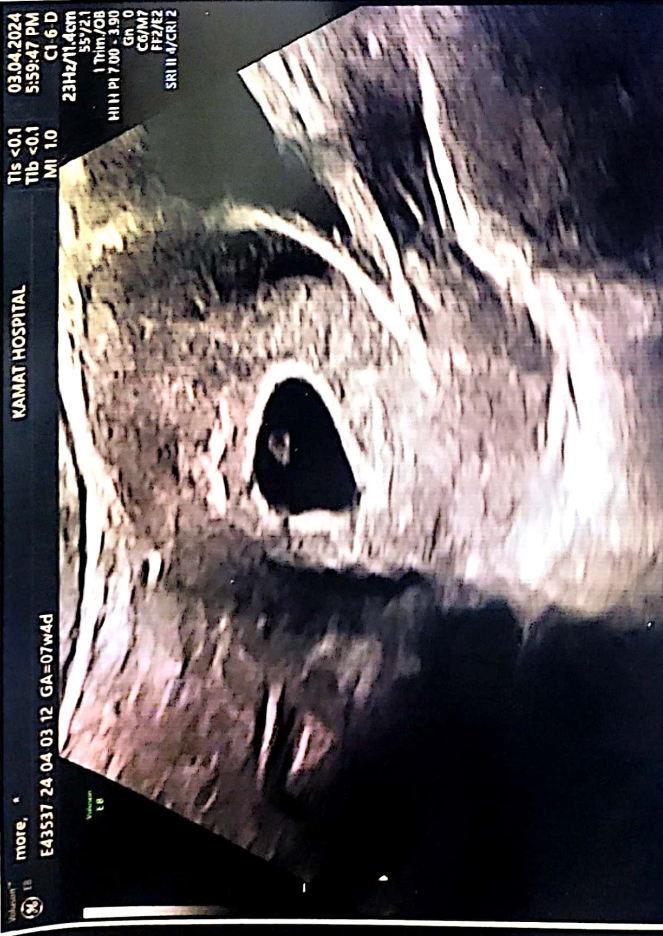
# KAMAT HOSPITAL

Name : more

03 Apr 2024







# KAMAT HOSPITAL

Department of Ultra Sonography & Colour Doppler

DATE : 21/03/24  
NAME : MRS PRATIKSHA MORE  
PRN NO : 24/0457  
REF.BY : DR D S KAMAT MD DGO FICOG FICA

## USG: PELVIS:

LMP: 10/02/24

Period of amenorrhoea: 5 weeks 5 days.

A single, smooth intrauterine gestational sac is seen.

Foetal pole is not yet seen inside the sac.

No signs of separation of the sac are seen.

Sac size is: 3 mms.

This corresponds to: about 5 weeks.

There is no parametrial mass or collection.

## CONCLUSION:

Single, smooth, intrauterine gestational sac is seen.

Suggest: follow up, to determine viability.

  
DR. KUNAL BEDSE, DMRE.

3/21/24, 4:14 PM

about:blank

### DECLARATION OF PREGNANT WOMAN

I, Mrs. ☒ PRATIKSHA ABHISHEK MORE

असे घोषित करते की अल्ट्रा-सोनोग्राफी/प्रतिमा स्कॅनिंग करून मी माझ्या गर्भाचे लिंग जाणून घेऊ इच्छित नाही. /declare that by undergoing ultrasonography/image scanning etc. I do not want to know the sex of my foetus.

गरोदर स्त्रीची सही/अंगठ्याचा ठसा./Signature/Thumb impression of pregnant woman

### DECLARATION OF DOCTOR

I, Dr. KUNAL SUDAM BEDSE

patient

☒ declare that while undergoing ultrasonography/image scanning on

Mrs. ☒ PRATIKSHA ABHISHEK MORE

I have neither detected nor disclosed the sex of her foetus to anybody in any manner.

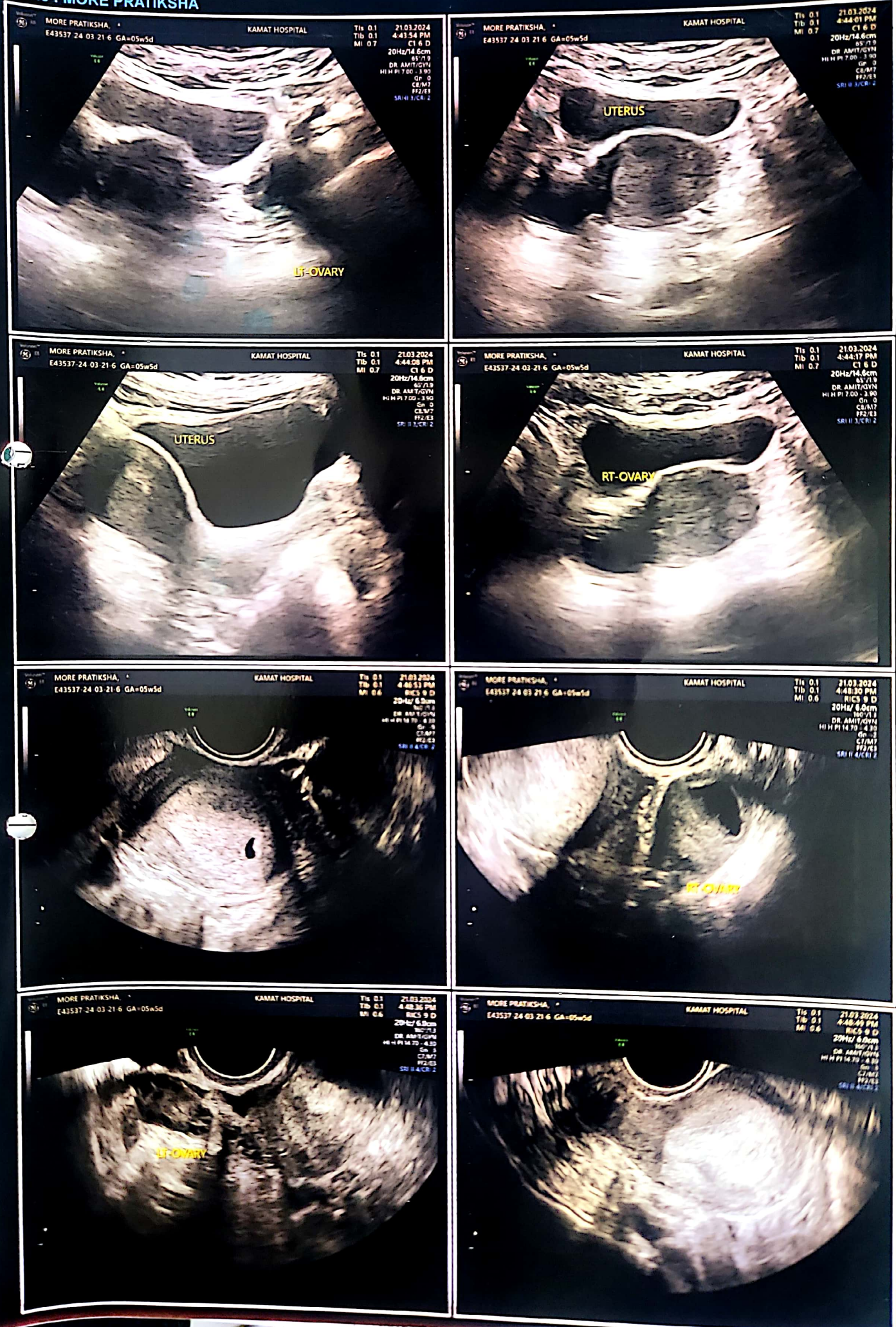
Signature of the person conducting Ultrasonography/image scanning/Director or owner of genetic clinic/ ultrasound clinic/imaging centre.

Dr. Kunal Bedse  
DMRE  
Reg No. 2013062302





Name : MORE PRATIKSHA







# KAMAT HOSPITAL

**Kamat Hospital**

Chaphekar Chowk, Chinchwadgaon,  
Pune  
Maharashtra 411033, India

PHONE: N/A

WEBSITE: N/A

## SQA-IO AUTOMATED SEMEN ANALYSIS RESULTS

SQA-IO MES - Signal Processing Technology

### PATIENT INFORMATION:

FIRST NAME:	ABHISHEK
PATIENT ID:	24478
REFERRING DOCTOR:	AMIT KAMAT

LAST NAME:	MORE
AGE:	24
PHONE NUMBER:	N/A

### SAMPLE INFORMATION:

SAMPLE ID:	24478
SAMPLE TYPE:	FRESH
COLLECTED DATE   TIME:	2/16/2024   1:00 PM
RECEIVED DATE   TIME:	2/16/2024   1:00 PM
TEST DATE   TIME:	2/16/2024   1:32 PM
CRITERIA:	WHO 6th
VOLUME (ml):	3
WBC CONC. (M/ml):	<1
pH:	8

DEBRIS:	Moderate 11% - 30%
APPEARANCE:	Clear/White/Grey
VISCOSITY:	Normal
LIQUEFACTION:	0-30 Minutes
ABSTINENCE (days):	3
SAMPLE TESTED:	FULL VOLUME
OPTIONAL 1:	N/A
OPTIONAL 2:	N/A

PARAMETER	RESULT	UNITS	REF VALUE	MOTILITY GRAPH
CONCENTRATION	95.0	M/ml	>=16	<p>(39%) (31%) (6%) (24%)</p> <ul style="list-style-type: none"> <li>Rapidly Progressive (%)</li> <li>Slowly Progressive (%)</li> <li>Non-Progressive (%)</li> <li>Immotile (%)</li> </ul>
MOTILITY	61	%	>=42	
PROGRESSIVE	55	%	>=30	
RAPIDLY PROGRESSIVE	31	%		
SLOWLY PROGRESSIVE	24	%		
NON-PROGRESSIVE	6	%	<=1	
IMMOTILE	39	%	<=20	
NORMAL FORMS	5	%	>=4	
MOTILE SPERM CONC.*	57.5	M/ml	>=6	
PROG. MOTILE SPERM CONC.*	51.7	M/ml	>=5	
RAPID PR. MOTILE SPERM CONC.*	29.3	M/ml		
SLOW PR. MOTILE SPERM CONC.*	22.4	M/ml		
FUNCTIONAL SPERM CONC.*	5.9	M/ml	>0.2	
VELOCITY (VCL)*	42	mic/sec	>=5	
SPERM MOTILITY INDEX*	216	—	>=80	

\*MES parameters are indicated by an asterisk







# KAMAT HOSPITAL

Department of Ultra Sonography & Colour Doppler

DATE : 14/02/24  
NAME : MRS. PRATIKSHA MORE  
PRN NO : 24/0457  
REF.BY : DR. D S KAMAT MD DGO FICOG FICA

## USG PELVIC: (TAS+TVS)

Uterus is of normal size, shape.

No obvious focal lesion is seen arising from the uterus.

Uterine size: 75 x 30 x 42 mm.

Endometrium is 6 mm.

Both ovaries are bulky. Ovarian volume - Right ovary : 13 cc ; Left ovary : 9 cc.

Few small cystic lesions are seen in the both ovaries.

There is no parametrial mass.

There is no free fluid in cul-de-sac.

## CONCLUSION:

Normal sized uterus.

Both ovaries are bulky and shows polycystic morphology.

No parametrial mass or collection.

DR. KUNAL BEDSE, DMRE.

Kamat Hospital

Chapekar Chowk, Chinchwad, Pune - 411 033. Ph: 2735 4777 / 2735 4888



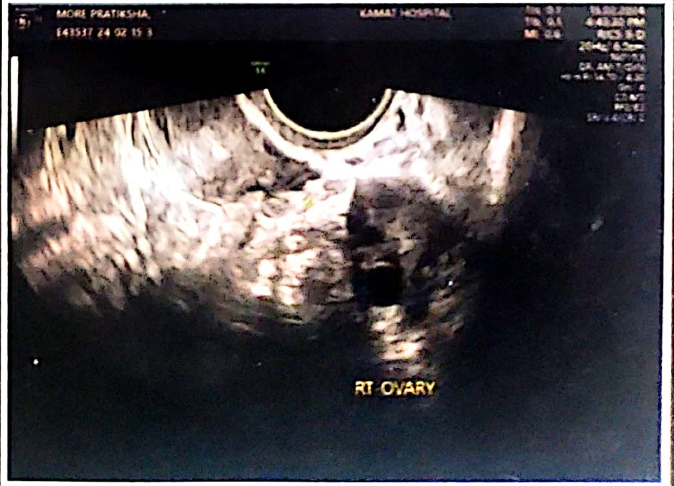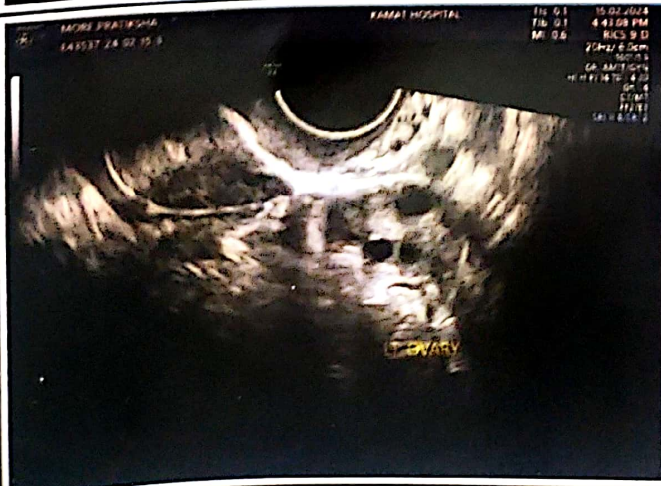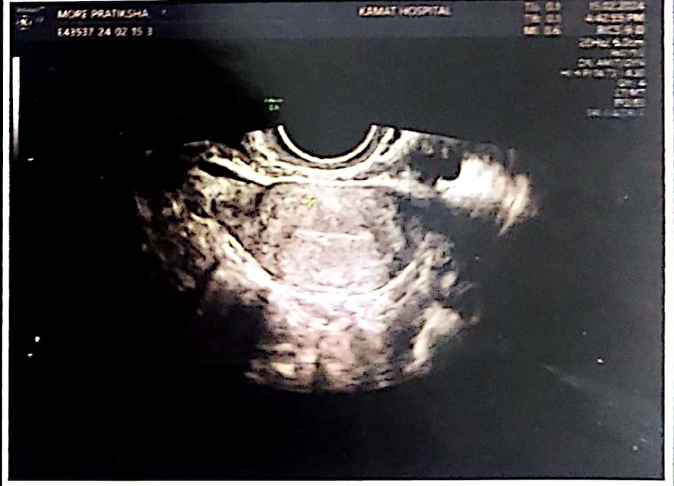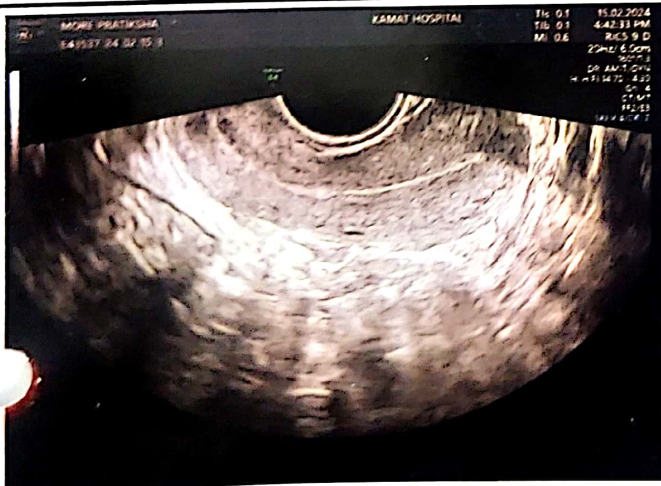
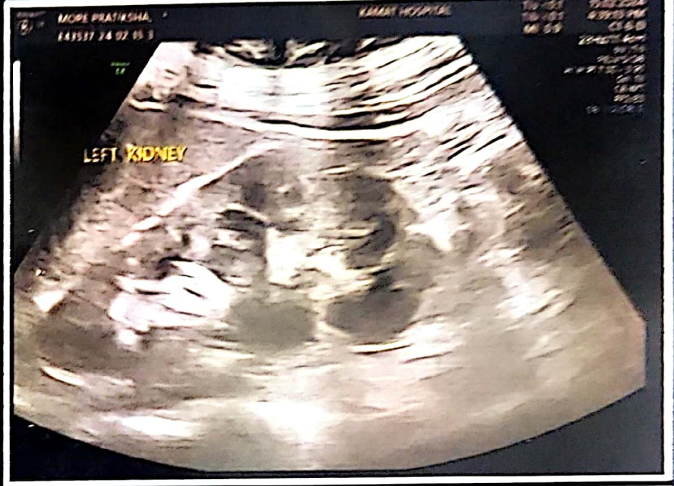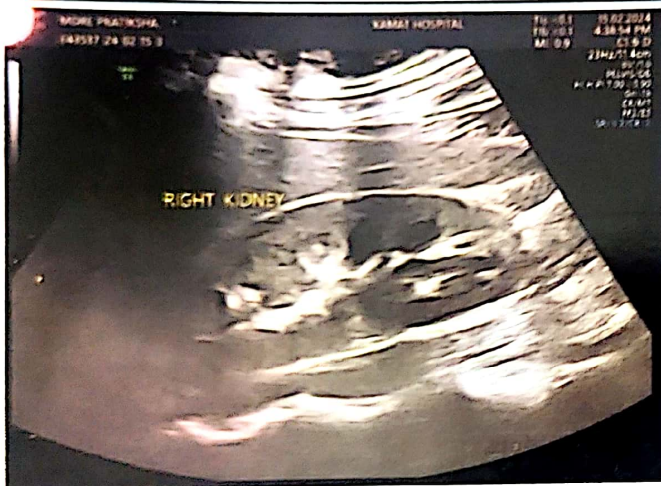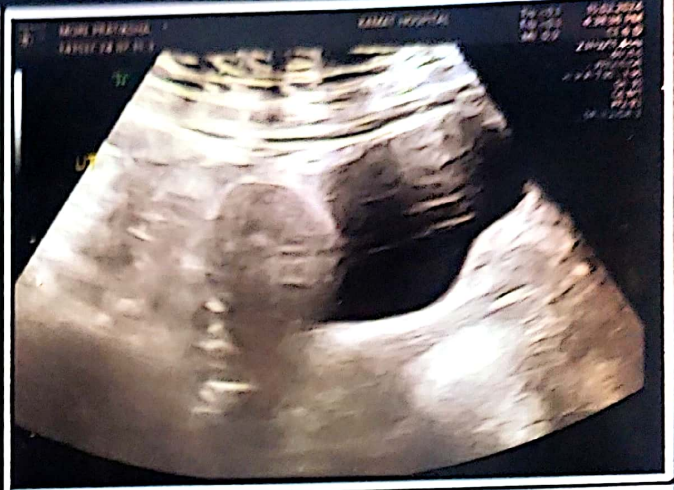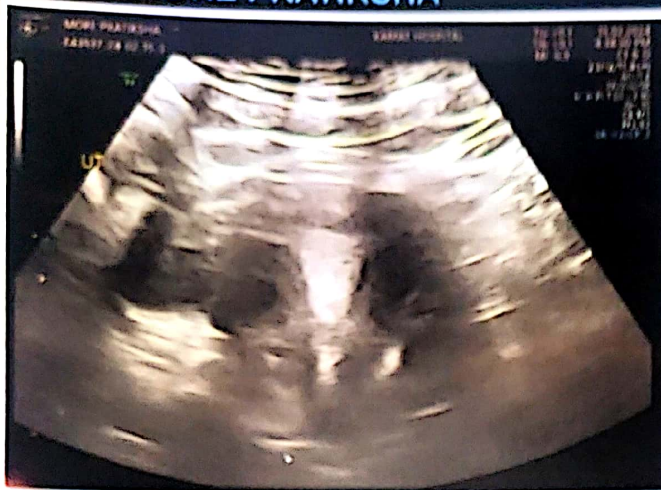
Scanned with OKEN Scanner




# KAMAT HOSPITAL

Name : MORE PRATIKSHA

15 Feb 2024







Dr. Kamat Hospital Healthcare Services LLP  
Chapekar Chowk, Chinchwad, Pune - 411033  
Phone No: 020-27354777/888  
Website : www.kamathospitalpcmc.com



## OUT PATIENT DEPARTMENT

### OPD CASE PAPER

OPD NO. : O/005386 Patient ID : KH/OPD/2024/0000457 Visit Date : 14/02/2024 09:01 AM

Name : Mrs. More Pratiksha Abhishek Age/Gender : 23 Yrs / Female  
Address : Flat no.102 Hindavi Nivas Patil nagar Chikhali Case No. :  
Phone No. : 9518323177  
Occupation : House Wife  
Spouse Occupation : Business(Hotel)  
Ref. Dr. : Kamat Dilip Shantaram  
Consultant : Kamat Dilip Shantaram  
Company Name : Self Paying  
Visit Description : Aadhar card (3247 8361 4754)  
Language : MARATHI  
Free Visit : Yes

Case Paper Date : 14 / Feb / 2024 To 13 / May / 2024 Height : 0 Cm Weight : 0 Kg

Name : Abhishek More Phone No. : 9011633636  
Address :

#### CHIEF COMPLAINTS :

Patient : WANTS TO CONCEIVE  
TRYING SINCE 5 MONTHS  
LMP: 10/02/24

Blood Group of Patient : A-Positive Blood Group of Spouse :  
Pregnancy : No

#### MARITAL + MENSTRUAL :

Marriage Status : Married From Last : 2 Year  
Remark : NON CONSANGUINOUS

#### MENSTRUAL

Age at Menarche : 14 Duration of Cycle : 28- 30 Days  
Duration of Bleed : 5 Days Flow : NORMAL  
Cycle : Regular

#### OBSTETRICS HISTORY

G : 1 P : 0 A : 1 L : 0 D : 0 E : 0

Contraception : NO

Gravida	Baby	Live	Age	Mode	Baby Wt	Indication	Dr/Place/Year
G1	None			1ST TRIMESTER MTP BY PILLS			19/07/22 SHREE HOSP. CHIKHALI

#### PERSONAL HISTORY

Allergy : NONE  
Diseases : NO  
Are you on any medications at present? : No



Have you received any blood transfusion in the past ? : No

**FAMILY HISTORY**

Father :Diabetes

**INFERTILITY HISTORY**

**INVESTIGATION**

USG : USG OBST (19/07/22) A SINGLEINTRAUTERINE GESTATIONAL SAC OF AGA 4-5 WEEKS







**Initial Nutritional Screening - OPD**  
**KH/SHCO/AAC - 3/F/00**

Registration No. :

Ward :

Date :

Patient's Name : Mrs. More Pratibha PRN : \_\_\_\_\_

Age: 23 Yrs. Sex : F Height : \_\_\_\_\_ cm Weight : \_\_\_\_\_ Kg

BMI : \_\_\_\_\_ Kg/m<sup>2</sup> (Underweight / Normal / Overweight / Obese)

Category	Underweight	Normal	Overweight	Obese
BMI (Kg/m <sup>2</sup> )	< 18	18 to 24	25 to 29	>30

**Nutritional Risk Factor:**

● Significant Weight Loss: Yes/No

● Anemia : Yes/No

● Nausea/ Vomiting/Diarrhea : Yes/No

● Food Allergy: Yes/No

If Yes, Specify: \_\_\_\_\_

Nutritional usual food intake Pattern : Very Poor / Probably Inadequate / Adequate / Excellent

Nutritional Reference required: Yes/ No,

Nutritional reference given to dietician: Date: \_\_\_\_\_ Time: \_\_\_\_\_

Doctors Name: Dr. SWATI.

Assessment Date: 14/2/24 Time: 10:46 am

