



# Global Diagnostics

## Sonography & Digital X Ray

### Dr. Shoaib (Soyaf) Fazlani

MBBS-GMC, NAGPUR, MD - Radiology - LTMMC (Sion Mumbai)  
DNB - Radiology - (NBE Delhi) Ex. Asst. Professor GMC, Nagpur  
Ex. Consultant Radiologist - Midas Hospital, Ramdaspath, Nagpur  
Consultant Radiologist & Sonologist

### Dr. Fiza Banu Fazlani

MBBS, DMRE, BCFRG  
Ex Trainee GMC, Nagpur  
Consultant Radiologist & Sonologist  
Reg. No. 2020/03/2389

Address : Shop No. G-7, Ground Floor, Anjuman Complex, Near Khan Pathology Opp. Governor Kothi, Main Road, Sadar Bridge Pillar No. 37, Nagpur. **Contact No. : 70837 50761**


Patient Name: **NEHA RAUT**

Date: **06/03/2025**

Ref Phy: **DR. SARIKA THAKARE MBBS MD**

Age/Sex: **29 Years / FEMALE**

### OBSTETRIC NT SCAN



Dating	LMP	GA		EDD
		Weeks	Days	
By LMP	LMP: 07/12/2024	12	5	13/09/2025
By USG		12	4	14/09/2025
AGREED DATING IS (BASED ON LMP)				

Real time USG of pelvis shows a gravid uterus with a **single** intra uterine gestational sac.

### FETAL SURVEY

Placenta developing **posteriorly**.

There is no evidence of subchorionic hemorrhage

Liquor - Normal the fetal pole and fetal activity are well appreciated.

Cervical length measures 3.7 cm . The internal OS is closed.

### Fetal biometry

	mm	weeks	days
Crown Rump Length	59.9	12	3
Biparietal Diameter	18.9	13	0
Head Circumference	71.2	12	6
Abdominal Circumference	56.0	12	3
Femoral Length	7.3	12	2
Heart Rate	169 Beats Per Minute.		
The Embryo attains 40 weeks of age on	14/09/2025		
Nuchal Translucency	1 mm 13%		
Nasal Bone	2.4 mm 11.9%		
Ductus Venosus Waveform	Normal waveform Pattern		

### FETAL STRUCTURES VISUALIZED

**HEAD / FACE / SPINE:** The falx is well visualized and is in the midline. The IT is well visualized and is normal. The spine is seen as 2 lines at this stage. Both orbits are same. Retronasal triangle shows presence of nasal bones and normal mandibular gap. Frontomaxillary angle is normal.

**THORAX:** The heart is central in the thoracic cavity. Four chamber heart show equal size inflows. Presence of V sign (connection of ductal arch and aortic arch) is noted on color Doppler in 3 vessel tracheal view.

**ABDOMEN:** The cord insertion in the anterior abdominal wall is well seen. The stomach is noted in the abdomen. Urinary bladder is visualized. Two umbilical arteries seen.

**EXTREMITIES:** Visualized upper limbs and lower limbs are normal bilaterally.





### Dr. Shoaib (Soyaf) Fazlani

MBBS-GMC, NAGPUR, MD - Radiology - LTMMC (Sion Mumbai)  
DNB - Radiology - (NBE Delhi) Ex. Asst. Professor GMC, Nagpur  
Ex. Consultant Radiologist - Midas Hospital, Ramdaspath, Nagpur  
Consultant Radiologist & Sonologist

### Dr. Fiza Banu Fazlani

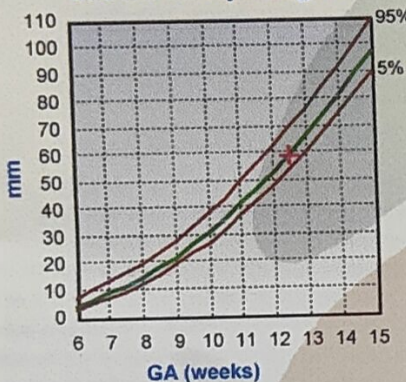
MBBS, DMRE, BCFRG  
Ex Trainee GMC, Nagpur  
Consultant Radiologist & Sonologist  
Reg. No. 2020/03/2389

Shop No. G-7, Ground Floor, Anjuman Complex, Near Khan Pathology Opp. Governor Kothi, Main Road, Sadar Bridge Pillar No. 37, Nagpur. **Contact No. : 70837 50761**

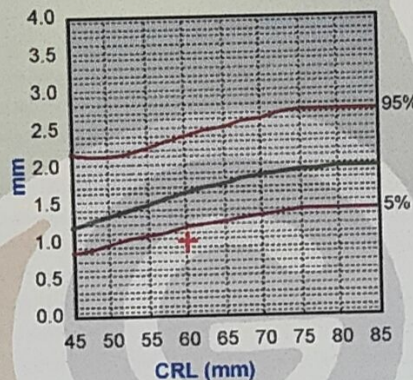
### UTERINE ARTERY SCREENING DOPPLER

Vessels	S/D	RI	PI	PI Percentile	Remarks
Right Uterine Artery	4	0.75	1.65	53.3%	No early Diastolic notch seen
Left Uterine Artery	4.66	0.79	2	78.6%	No early Diastolic notch seen
Mean Uterine Artery			1.83	69%	Normal
Ductus venosus	4.87		1.21		PSV= Normal waveform Pattern

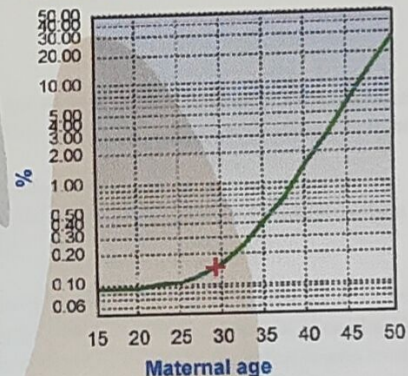
### Crown-rump length



### Nuchal translucency



### 1st trimester risk of Trisomy 21



First trimester: Pre Ultrasound Maternal age risk for Trisomy 21 is 1 in 461

T21 Risk	
From - NT	1 in 4088

### IMPRESSION:

- Early single live intra uterine gestation of 12 week's 4 days- gestational age assigns as per biometry . Fetus is appropriate for gestational age. (expected by LMP 12 weeks 5 days )
- Nuchal translucency is normal
- No gross congenital anomaly seen at this stage
- Placenta is developing posteriorly. Liquor - Normal
- Cervix measuring 3.7 cm, the internal os is closed

Suggested dual marker correlation and anomaly scan at 18-20 weeks

**PLEASE NOTE:** 1) this is machine depended that to image oriented investigation. Hence many things can influence appearance and interpretation of image. 2) In case of disparity between report and clinical evaluation second opinion is advisable before commencing the final treatment. 3) This document is not for medicolegal purpose

I, Dr. SHOAIB A. FAZLANI declare that while conducting ultrasonography on this patient, I have neither detected nor disclosed the sex of her fetus to anybody in any manner.

**DR. SHOAIB A FAZLANI**  
MBBS, MD, DNB, BCFRG  
CONSULTANT RADIOLOGIST

TYPED BY: HAAZ AHMED

**Dr. Shoaib Fazlani**  
MBBS, MD DNB (Radiology)  
Reg. No. 2014 / 07/3296





Time : 10 am to 3 pm  
6 pm to 9 pm

# Global Diagnostics

## Sonography & Digital X Ray

**Dr. Shoaib (Soyaf) Fazlani**

MBBS-GMC, NAGPUR, MD - Radiology - LTMMC (Sion Mumbai)  
DNB - Radiology - (NBE Delhi) Ex. Asst. Professor GMC, Nagpur  
Ex. Consultant Radiologist - Midas Hospital, Ramdaspath, Nagpur  
Consultant Radiologist & Sonologist

**Dr. Fiza Banu Fazlani**

MBBS, DMRE, BCFRG  
Ex Trainee GMC, Nagpur  
Consultant Radiologist & Sonologist  
Reg. No. 2020/03/2389

Shop No. G-7, Ground Floor, Anjuman Complex, Near Khan Pathology Opp. Governor Kothi, Main Road, Sadar Bridge Pillar No. 37, Nagpur. **Contact No. : 70837 50761**

### DISCLAIMER (NT)

- Patient's identity and contact details are based on her own declaration.
- This investigation has been done as per request of the referring doctor.
- In spite of utmost care taken, the measurement are subject to statistical variations.
- If there are no abnormalities found on scan, this is not a guarantee of a healthy child as there is a significant variability in the sensitivity of routine ultrasonography for detection of various fetal anomalies.
- Science of ultrasound, Ultrasonography machine and probe, all have their own limitations. Even the most sophisticated USG machine can make error in interpreting echoes and has T limitations in diagnosing lesions.
- The quality of the ultrasound image also depends on many factors, including the position of the baby, amniotic fluid volume, fetal movements, maternal abdominal wall thickness, multiple pregnancy etc. by ultrasonography is based on various echoes and shadows produced by both normal & abnormal tissues. Variety of disease process may produce similar echopattern or shadows.
- Further investigations and follow up scans may be necessary to confirm a positive test result.
- Disparity in final diagnosis can occur due to technical pitfalls like False Positive and False Negative results. Hence, only the report should not be taken as final diagnosis but should be correlated clinically with /or other investigations. In case of disparity between report and clinical evaluation, second opinion is always advisable before commencing final treatment.
- *Some anomalies may not be seen until later in your pregnancy.*
- Some anomalies are not detectable by ultrasound.
- For rate of detection of individual anomaly, list of anomalies detected in late pregnancy, and anomalies which cannot be detected on ultrasound the reader is referred to complete document published by MCR which is available on website [www.msblria.org](http://www.msblria.org) or at this clinic / hospital on demand.
- If any scan reveals a serious problem, your clinician will make you aware of the possible options.
- The ABOVE information provided is as per current literature available Neither the Society nor any of its employees or members accepts any liability for the consequences of any inaccurate or misleading data, opinions or statements.

### NT NB Scan as part of First Trimester Screening (between 11 weeks-13 weeks and 6 days):

The NT/ NB (Nuchal Translucency/ Nasal Bone) Scan a highly specialized ultrasound and takes a reasonable time. Apart from the information obtained in an early pregnancy scan, this scan provides additional parameters like nuchal translucency (skin fold on the back of fetal neck), presence of nasal bone, blood flow across the valve of the right heart chamber (tricuspid regurgitation) and blood across the ductus venosus. Tricuspid regurgitation is seen in 55% of trisomy 21 fetuses, 30% of 1 trisomy 18 fetuses & in about 1% of chromosomally normal fetuses. TR is trivial if not associated with cardiac defects & TR is severe if associated with cardiac defects.

Ductus venosus flow reversal is seen in chromosomal anomalies, cardiac defects, twin transfusion syndrome in monochorionic twins

### Following is the list of Detection rate of Anomalies at 11-13 weeks scan

• Absent hand / foot	7%
• Polydactyly	0%
• Diaphragmatic hernia	0%
• Lethal skeletal dysplasia	0%
• Cleft palate	4%
• Open spina bifida	4%
• Ventriculomegaly	9%

### Following is the list of anomalies cannot be diagnosed at 11-13 weeks scan

- Neural tube, brain, face - Hemivertebra Microcephaly, Craniosynostosis, Agenesis of corpus callosum, Semilobar Holoprosencephaly, Cerebellar Hypoplasia, Vermian agenesis, Nasopharyngeal teratoma, Retrognathia
- Lungs, Heart - Cystic adenomatoid malformation, Extralobar sequestration, Isolated VS, Cardiac tumors
- Abdominal, Renal - Duodenal atresia, Bowel obstruction,
- Renal agenesis - Bilateral, unilateral, Multicystic kidneys, Hydronephrosis, Duplex kidneys, Bladder exstrophy,
- Other - Arthrogryposis, Talipes, Ectrodactyly

### Following are false positive structural anomaly findings in 11-13 weeks scan

- Echogenic choroid plexus, Omphalocele, Discrepancy in size of great vessels, Megacystis, Intra-abdominal cyst, Cleft Palate

To determine the risk of having a fetus with chromosomal abnormality (like Down's Syndrome, trisomy 18, trisomy 13) your clinician will combine the report of this test and serum biochemistry. In case of a positive result (showing an increased risk) you may have to undergo further diagnostic tests. It is important to note that a positive result in first trimester screening does not mean that your baby has a chromosomal anomaly and a negative or normal result (one that shows a decreased risk) does not mean that the baby will not have a chromosome abnormality. Further investigations and follow up scans may be necessary to confirm a positive test result.

I/We have read the above information and understand the implications.

Place: GLOBAL DIAGNOSTICS, NAGPUR

Date: 06 Mar. 25

Signature of women Undergoing Ultrasound



