



SHRI SIDDHIVINAYAK DIAGNOSTIC CENTRE

Near HDFC Bank, Daund-Patas Road, Daund, Dist. Pune - 413801. Mo.: 9028760100, 9028992600

| | | | | | |
|-------------|---|--------------------------|--------|---|-------------|
| PATIENT | : | MRS. SNEHA DIPAK BHAGWAT | AGE | : | 32 YEARS |
| Patient ID- | : | 9570 | GENDER | : | F |
| REF. BY | : | Dr. RAHUL JAGDALE SIR -- | DATE | : | 16 Mar 2025 |

OBSTETRICS ULTRASOUND (NT SCAN)

LMP: 11/12/2024

GA By LMP: 13 weeks 04 days

EDD By LMP: 17/09/2025

GA By USG: 13 weeks 06 days

EDD By USG: 15/09/2025

* Single live intrauterine fetus noted with changing lie

* CRL: 7.7 cm corresponding to 13 weeks 06 days

* Fetal cardiac activity present (FHR= 149 bpm)

* Nasal bone echo seen

* Ductus venosus Doppler: Triphasic wave pattern

* Nuchal Translucency measures: 1.6 mm

* Placenta developing posterior wall

* Cervical length measures 3.1 cm

* Visualised limbs, spine and fetal skull appears normal

* Internal os is closed



Real time pulsed Doppler done with colour flow mapping

| | PI (cm/sec) | RI (cm/sec) | S/D Ratio |
|----------------------|----------------|----------------|-----------|
| Right uterine artery | 0.7 | 0.5 | 2.0 |
| Left uterine artery | 0.6 | 0.4 | 1.7 |

Bilateral uterine arteries show normal systolic and diastolic flow


IMPRESSION:

- Single live intrauterine gestation of 13 weeks 06 days
- Double marker test- 8 to 14 weeks // Triple marker test- 15 to 18 weeks

Suggest anomaly scan at 18-22 weeks. (27 April 2025)

All congenital anomalies are not detected by sonography and are subject to fetal position and advanced gestational age. All measurements including birth weight are subject to statistical variations

* I **Mrs. SNEHA BHAGWAT**, declare that by undergoing ultrasonography/image scanning etc. I do not want to know the sex of my fetus



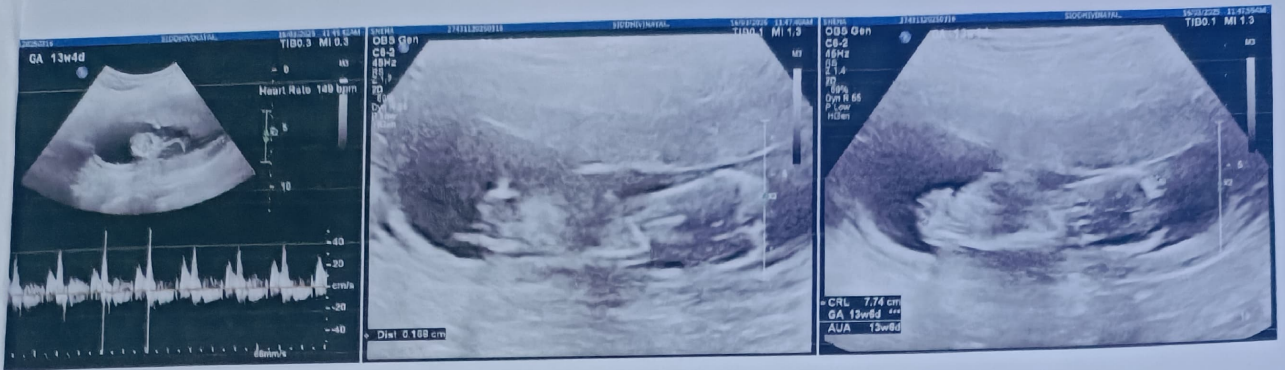Signature of pregnant women *

I, **Dr. RISHIKESH PATIL**, declare that while conducting ultrasonography/image scanning etc. on **Mrs. SNEHA BHAGWAT**, I have neither detected nor declared sex of her fetus to anybody in any manner

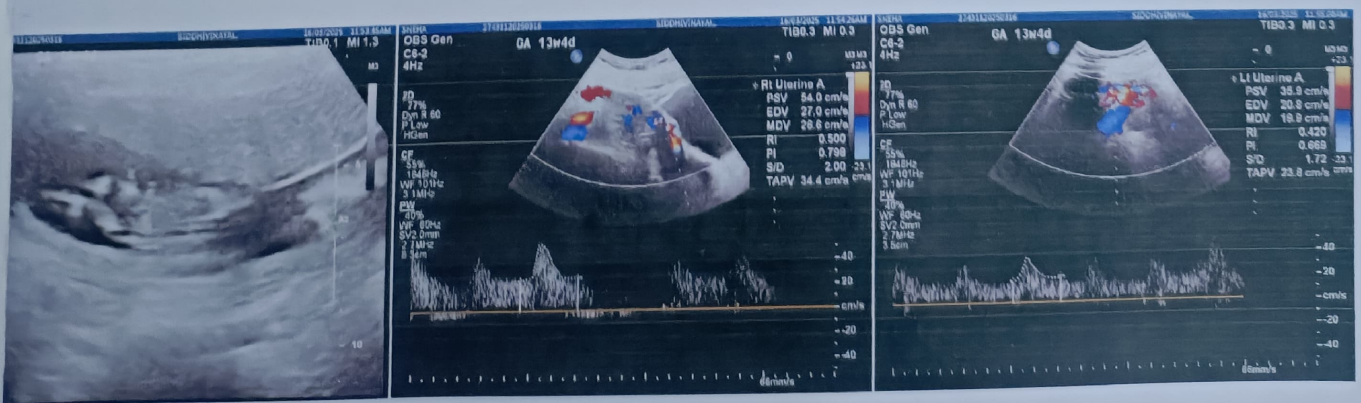
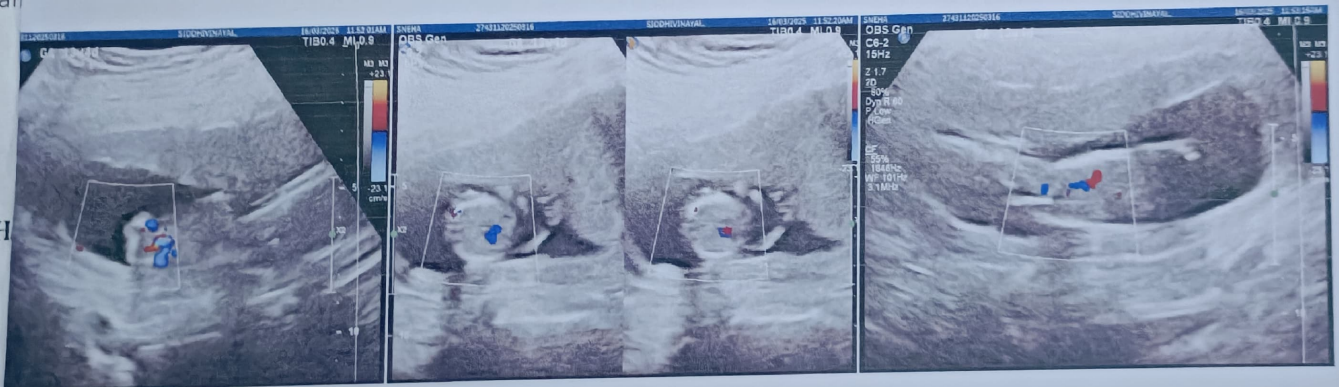
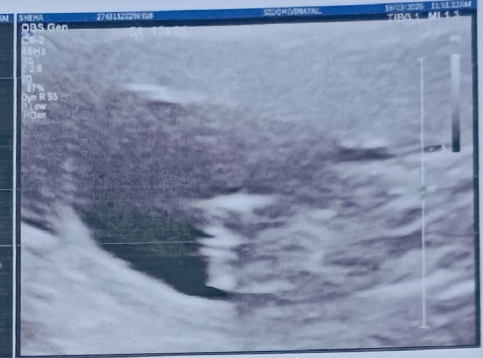
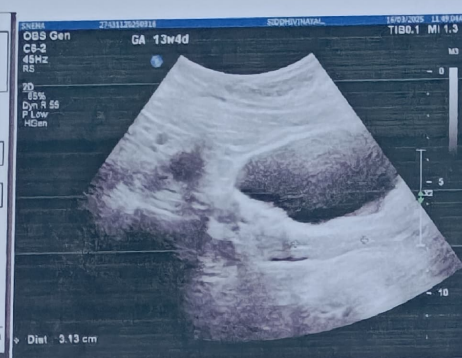
DR. RISHIKESH P.
CONSULTANT RADIOLOGIST

This is a professional opinion, not the final diagnosis & should be interpreted in the light of clinical background. This report is not for medico legal purposes. Always suggest a second opinion if clinical indicated.



| GA | Weight | Length | Head Circ | SD | Percentile |
|-------|--------|--------|-----------|----|------------|
| 13w4d | 7.74 | 6.18 | 13.9 | 50 | 50 |





SHRI SIDDHIVINAYAK DIAGNOSTIC CENTRE

Near HDFC Bank, Daund-Patas Road, Daund, Dist. Pune - 413801. Mo. : 9028760100, 9028992600

| | | | | | |
|-------------|---|--------------------------|--------|---|-------------|
| PATIENT | : | MRS. SNEHA DIPAK BHAGWAT | AGE | : | 32 YEARS |
| Patient ID- | : | 9321 | GENDER | : | F |
| REF. BY | : | Dr. RAHUL JAGDALE SIR -- | DATE | : | 11 Feb 2025 |

OBSTETRICS ULTRASOUND

L.M.P : 10/12/2024

G.A. BY L.M.P. : 07 weeks 07 days

G.A. BY U.S.G. : 08 weeks 06 days

E.D.D. BY U.S.G.: 7/05/2025

Uterus is bulky and shows a single well defined gestational sac in it with Healthy decidual reaction

Fetal pole seen

Single Amniotic cavity and amnion is seen

CRL: 2.2 cm corresponding to 08 weeks 06 days

Fetal cardiac activity present (FHR = 160 bpm, Normal and Regular)

Cervical canal is normal. Cervical length is 2.9 cm

Internal os is closed


IMPRESSION:

- Single live intrauterine gestation of 08 weeks 06 days
- Suggest follow-up ultrasound for NT scan (15 March 2025)




All congenital anomalies are not detected by sonography and are subject to fetal position and advanced gestational age. All measurements including birth weight are subject to statistical variations.

* I **Mrs. SNEHA BHAGWAT**, declares that by undergoing ultrasonography/image scanning etc. I do not wish to know the sex of my fetus.




Signature of pregnant women *

I, Dr. **RISHIKESH PATIL**, declare that while conducting ultrasonography/image scanning etc. on Mrs. **SNEHA BHAGWAT**, I have neither detected nor declared sex of her fetus to anybody in any manner.

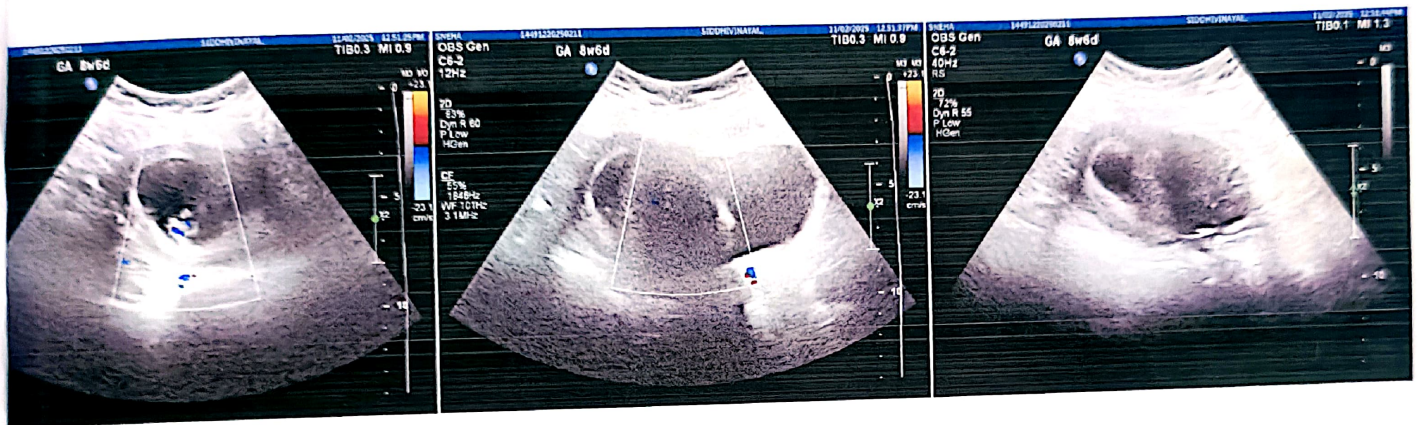


DR. RISHIKESH PATIL
CONSULTANT RADIOLOGIST

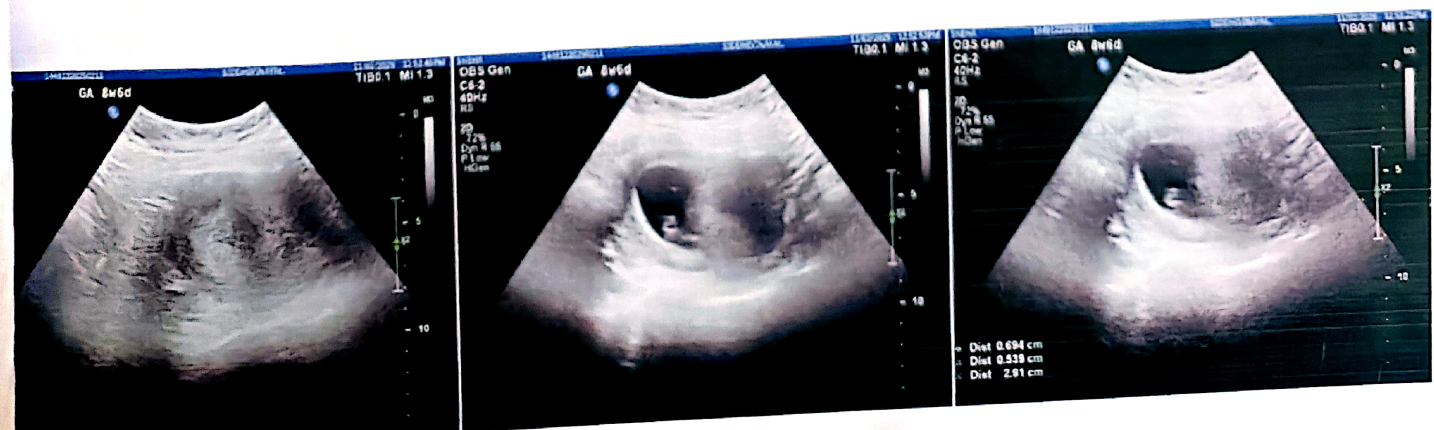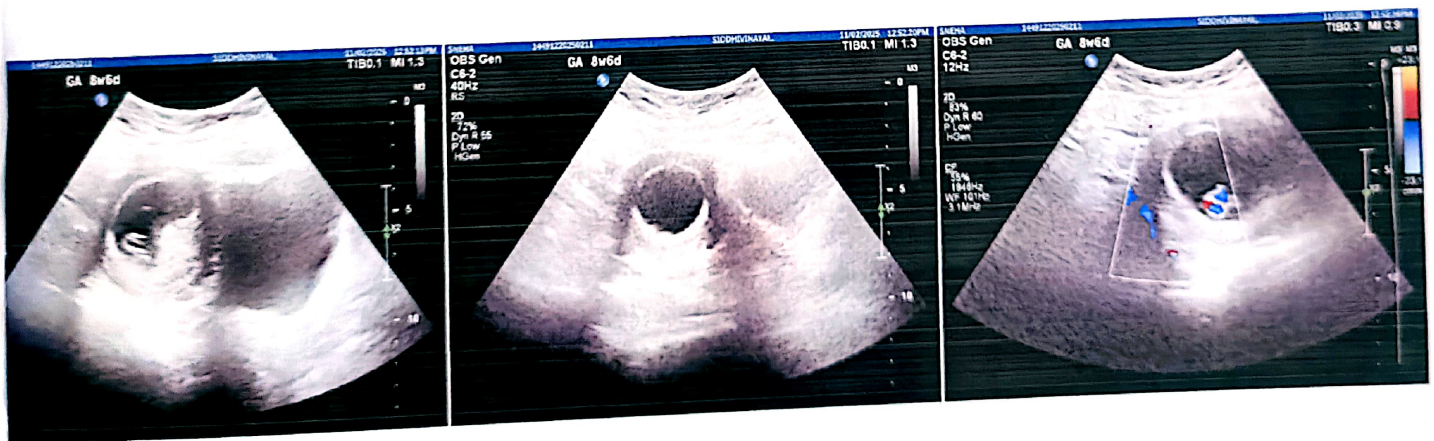
This is a professional opinion, not the final diagnosis & should be interpreted in the light of clinical background. This report is not for medico legal purposes. Always suggest a second opinion if clinical indicated.



ant



it for





SHRI SIDDHIVINAYAK DIAGNOSTIC CENTRE

Near HDFC Bank, Daund-Patas Road, Daund, Dist. Pune - 413801. Mo. : 9028760100, 9028992600

| | | | | | |
|-------------|---|--------------------------|--------|---|-------------|
| PATIENT | : | MRS. SNEHA DIPAK BHAGWAT | AGE | : | 32 YEARS |
| Patient ID- | : | 9187 | GENDER | : | F |
| REF. BY | : | Dr. RAHUL JAGDALE SIR -- | DATE | : | 27 Jan 2025 |

OBSTETRICS ULTRASOUND

L.M.P: 18/12/2024

Uterus is bulky and shows a single well defined gestational sac in it.

No Fetal pole seen.

No Yolk sac seen.

Sub chorionic collection is seen fundo anterior to G sac, as measure 6 X 5 mm
G sac measures 1.1 cm corresponding to 5 weeks 6 days.

Cervical canal is normal. Cervical length is 3.1 cm

Internal os is closed.

IMPRESSION:


- *Uterus is bulky and shows a single gestational sac in it, mean gestational sac measures 1.1 cm corresponding to 5 weeks 6 days.*
- *Sub chorionic collection as mentioned above*

Suggest follow-up ultrasound for fetal viability on dated (15 Feb 2025)




All congenital anomalies are not detected by sonography and are subject to fetal position and advanced gestational age. All measurements including birth weight are subject to statistical variations.

* I **Mrs. SNEHA BHAGWAT**, declares that by undergoing ultrasonography/image scanning etc. I do not want to know the sex of my fetus.



Signature of pregnant women *

I, **Dr. RISHIKESH PATIL**, declare that while conducting ultrasonography/image scanning etc. on **Mrs. SNEHA BHAGWAT**, I have neither detected nor declared sex of her fetus to anybody in any manner.



DR. RISHIKESH PATIL
CONSULTANT RADIOLOGIST

This is a professional opinion, not the final diagnosis & should be interpreted in the light of clinical background. This report is not for medico legal purposes. Always suggest a second opinion if clinical indicated.

