

L-162 Dr Surface Scan 25117

Double

Measure

Height → 5-Ft-4 In

WT → 599 kg

D.O.B → 14/12/1999

# Engineering, Technology & Training Planning

[illegible]

LH-A-011654

Mobile No.: 8966008418

Date : 21-Mar-2025

BP 11117-2

Page 106/108

8902954

201 59.98

4/2/20

25

Das Daxinot m  
 der Kammell m

Das Alter noch

22 Jan 1948  
34

From

2-1

R



# डॉ. अंकिता विजयवर्गीय

एम. बी. बी. एस., डी. एम. आर. डी  
एम. आर. आई. फेलोशिप :  
नानावटी हॉस्पिटल, मुंबई  
हिंदुजा हॉस्पिटल, मुंबई  
सिडियोलाजिस्ट :  
फोर्टिस हॉस्पिटल, नोएडा  
डी. टी. बी. हॉस्पिटल, दिल्ली  
रेजीसी हॉस्पिटल लिमिटेड, कानपुर  
जाह्निक लाल नेहरू कैंसर हॉस्पिटल, भोपाल

## DR. ANKITA VIJAYVARGIYA MBBS, DMRD

### MRI FELLOWSHIPS :

- NANAVATI HOSPITAL, MUMBAI
- HINDUJA HOSPITAL, MUMBAI

FMF Certified from  
Fetal Medicine Foundation  
Reg. No. MP-8932

### FORMER RADIOLOGIST AT:

- FORTIS HOSPITAL, NOIDA
- G.T.B HOSPITAL, DELHI
- REGENCY HOSPITAL LTD, KANPUR
- JAWAHAR LAL NEHRU CANCER HOSPITAL, BHOPAL

PATIENT'S NAME : DR. SAPNA

AGE/SEX : 25Y/F

REF. BY : DR. POOJA SHRIVASTAVA (MBBS, MS)

DATE : 20.03.2025

### OBSTETRIC USG (EARLY ANOMALY SCAN)

LMP: 18.12.2024

GA(LMP):13wk 1d

EDD : 24.09.2025

- Single live fetus seen in the intrauterine cavity in variable presentation.
- Spontaneous fetal movements are seen. Fetal cardiac activity is regular and normal & is 151 beats /min.
- PLACENTA: is grade I, anterior & not low lying.
- LIQUOR: is adequate for the period of gestation.

#### Fetal morphology for gestation appears normal.

- Cranial ossification appears normal. Midline falx is seen. Choroid plexuses are seen filling the lateral ventricles. No posterior fossa mass seen. Spine is seen as two lines. Overlying skin appears intact.
- No intrathoracic mass seen. No TR.
- Stomach bubble is seen. Bilateral renal shadows is seen. Anterior abdominal wall appears intact.
- Urinary bladder is seen, appears normal. 3 vessel cord is seen.
- All four limbs with movement are seen. Nasal bone well seen & appears normal. Nuchal translucency measures 1.8 mm ( WNL ).
- Ductus venosus shows normal flow & spectrum with positive "a" wave ( PI ~ 1.08 )

#### FETAL GROWTH PARAMETERS

- |   |
|---|
| ▪ CRL 72.1 mm ~ 13 wks 3 days of gestation. |
|---|

- Estimated gestational age is 13 weeks 3 days (+/- 1 week). EDD by USG : 22.09.2025
- Internal os closed. Cervical length is WNL ( 38.6 mm ).
- Baseline screening of both uterine arteries was done with mean PI ~ 1.67( WNL for gestation ).

#### IMPRESSION:

- Single, live, intrauterine fetus of 13 weeks 3 days +/- 1 week.
- Gross fetal morphology is within normal limits.

Follow up at 19-22 weeks for target scan for detailed fetal anomaly screening.

Declaration : I have neither detected nor disclosed the sex of the fetus to pregnant woman or to anybody. (It must be noted that detailed fetal anatomy may not always be visible due to technical difficulties related to fetal position, amniotic fluid volume, fetal movements, maternal abdominal wall thickness & tissue ecogenicity. Therefore all fetal anomalies may not be detected at every examination. Patient has been counselled about the capabilities & limitations of this examination. )

( DR. ANKITA VIJAYVARGIYA )



हॉस्पिटल, दिल्ली  
हॉस्पिटल लिमिटेड, कानपुर  
हॉस्पिटल, भोपाल

**MRI FELLOWSHIPS :**

- NANAVATI HOSPITAL, MUMBAI
- HINDUJA HOSPITAL, MUMBAI
- FORTIS HOSPITAL, NOIDA
- G.T.B HOSPITAL, DELHI
- REGENCY HOSPITAL LTD, KANPUR
- JAWAHAR LAL NEHRU CANCER HOSPITAL, BHOPAL

**DR. ANKITA JAYVARGIYA**  
MBBS, DMRD

FMF Certified from  
Fetal Medicine Foundation  
Reg. No. MP-8932

PATIENT'S NAME : DR. SAPNA

REF. BY : DR. POOJA SHRIVASTAVA (MBBS, MS)

AGE/SEX : 25Y/F

DATE : 20.03.2025

LMP: 18.12.2024

**OBSTETRIC USG (EARLY ANOMALY SCAN)**

GA(LMP):13wk 1d

EDD : 24.09.2025

- Single live fetus seen in the intrauterine cavity in variable presentation.
- Spontaneous fetal movements are seen. Fetal cardiac activity is regular and normal & is 151 beats/min.
- PLACENTA: is grade I, anterior & not low lying.
- LIQUOR: is adequate for the period of gestation.

**Fetal morphology for gestation appears normal.**

- Cranial ossification appears normal. Midline falx is seen. Choroid plexuses are seen filling the lateral ventricles. No posterior fossa mass seen. Spine is seen as two lines. Overlying skin appears intact.
- No intrathoracic mass seen. No TR.
- Stomach bubble is seen. Bilateral renal shadows is seen. Anterior abdominal wall appears intact.
- Urinary bladder is seen, appears normal. 3 vessel cord is seen.
- All four limbs with movement are seen. Nasal bone well seen & appears normal. Nuchal translucency measures 1.8 mm (WNL).
- Ductus venosus shows normal flow & spectrum with positive "a" wave (PI ~ 1.08)

**FETAL GROWTH PARAMETERS**

|     |      |    |   |    |       |   |                    |
|-----|------|----|---|----|-------|---|--------------------|
| CRL | 72.1 | mm | ~ | 13 | weeks | 3 | days of gestation. |
|-----|------|----|---|----|-------|---|--------------------|

- Estimated gestational age is 13 weeks 3 days (+/- 1 week). EDD by USG : 22.09.2025
- Internal os closed. Cervical length is WNL (38.6 mm).
- Baseline screening of both uterine arteries was done with mean PI ~ 1.67 (WNL for gestation).

**IMPRESSION:**

- Single, live, intrauterine fetus of 13 weeks 3 days +/- 1 week.
- Gross fetal morphology is within normal limits.

Follow up at 19-22 weeks for target scan for detailed fetal anomaly screening.

Declaration : I have neither detected nor disclosed the sex of the fetus to pregnant woman or to anybody. (It must be noted that detailed fetal anatomy may not always be visible due to technical difficulties related to fetal position, amniotic fluid volume, fetal movements, maternal abdominal wall thickness & tissue ecogenicity. Therefore all fetal anomalies may not be detected at every examination. Patient has been counselled about the capabilities & limitations of this examination.)

(DR. ANKITA JAYVARGIYA)



# First Trimester Screening Report

Preeclampsia before 34 weeks

1: 2287

Fetal growth restriction before 37 weeks

1: 203

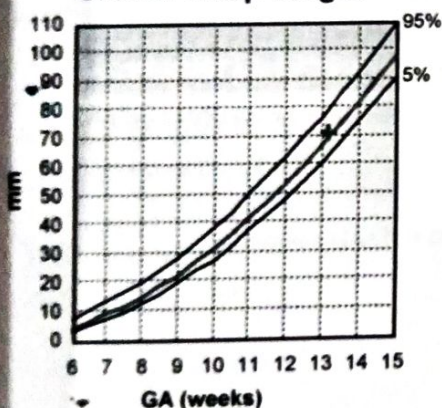
The background risk for aneuploidies is based on maternal age (25 years). The adjusted risk is the risk at the time of screening, calculated on the basis of the background risk and ultrasound factors (fetal nuchal translucency thickness, nasal bone, tricuspid Doppler, ductus venosus Doppler, fetal heart rate).

Risks for preeclampsia and fetal growth restriction are based on maternal demographic characteristics, medical and obstetric history, uterine artery Doppler and mean arterial pressure (MAP).

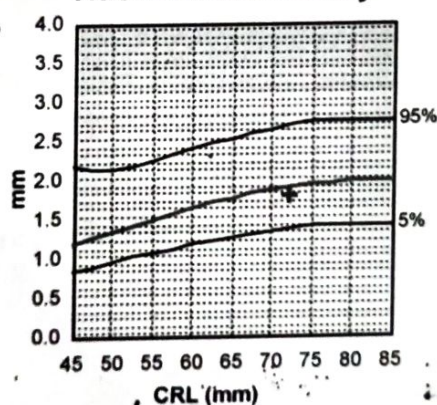
All biophysical markers are corrected as necessary according to several maternal characteristics including racial origin, weight, height, smoking, method of conception and parity.

The estimated risk is calculated by the FMF-2012 software (version 2.81) and is based on findings from extensive research coordinated by the Fetal Medicine Foundation (UK Registered charity 1037116). The risk is only valid if the ultrasound scan was performed by a sonographer who has been accredited by the Fetal Medicine Foundation and has submitted results for regular audit (see [www.fetalmedicine.com](http://www.fetalmedicine.com)).

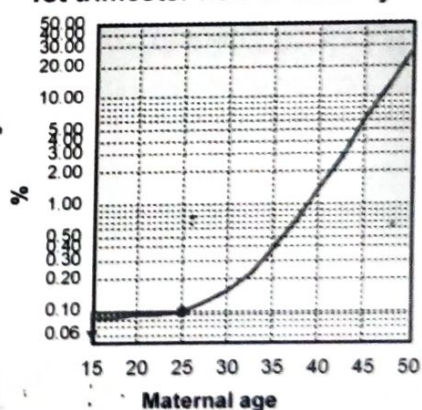
Crown-rump length



Nuchal translucency



1st trimester risk of Trisomy 21



# First Trimester Screening Report

Soni Dr. sapna

Date of birth : 14 December 1999, Examination date: 20 March 2025

Address: hno. hig-10, uma vihar kolar  
road  
Bhopal  
INDIA

Referring doctor: DR. (MS) POOJA SHRIVASTAVA

## Maternal / Pregnancy Characteristics:

Racial origin: South Asian (Indian, Pakistani, Bangladeshi).

Parity: 0.

Maternal weight: 60.0 kg; Height: 162.6 cm.

Smoking in this pregnancy: no; Diabetes Mellitus: no; Chronic hypertension: no; Systemic lupus erythematosus: dont know; Antiphospholipid syndrome: dont know; Patient's mother had preeclampsia: no.

Method of conception: Spontaneous;

Last period: 18 December 2024




EDD by dates: 24 September 2025

## First Trimester Ultrasound:

US machine: logiq f6. Visualisation: good.

Gestational age: 13 weeks + 1 days from dates

EDD by scan: 24 September 2025

|                          |               |   |
|--------------------------|---------------|---|
| Findings                 | Alive fetus   |   |
| Fetal heart activity     | visualised    |   |
| Fetal heart rate         | 151 bpm       |  |
| Crown-rump length (CRL)  | 72.1 mm       |  |
| Nuchal translucency (NT) | 1.8 mm        |   |
| Ductus Venosus PI        | 1.080         |  |
| Placenta                 | anterior high |   |
| Amniotic fluid           | normal        |   |
| Cord                     | 3 vessels     |   |

## Chromosomal markers:

Nasal bone: present; Tricuspid Doppler: normal.

## Fetal anatomy:

Skull/brain: appears normal; Spine: appears normal; Heart: 4 chamber & 3vessel trachea view grossly unremarkable; Abdominal wall: appears normal; Stomach: visible; Bladder/ Kidneys: visible; Hands: both visible; Feet: both visible.

|                         |           |                         |
|-------------------------|-----------|-------------------------|
| Uterine artery PI:      | 1.67      | equivalent to 1.080 MoM |
| Mean Arterial Pressure: | 74.6 mmHg | equivalent to 0.890 MoM |
| Endocervical length:    | 38.6 mm   |                         |

## Risks / Counselling:

Patient counselled and consent given.

Operator: DR. ANKITA VIJAYVARGIYA, FMF Id: 204664

| Condition  | Background risk | Adjusted risk |
|------------|-----------------|---------------|
| Trisomy 21 | 1: 977          | 1: 19538      |
| Trisomy 18 | 1: 2477         | <1: 20000     |
| Trisomy 13 | 1: 7746         | <1: 20000     |