

अंकिता विजयवर्गीय

पी. एस., डी. एम. आर डी

आई. फेलोशिप :

हॉस्पिटल, मुंबई

स्पिटल, मुंबई

लाजिस्ट :

स्पिटल, नोएडा

बी. हॉस्पिटल, दिल्ली

स्पिटल लिमिटेड, कानपुर

लाल नेहरू कैंसर हॉस्पिटल, भोपाल

DR. ANKITA VIJAYVARGIYA MBBS, DMRD

MRI FELLOWSHIPS :

• NANAATI HOSPITAL, MUMBAI

• HINDUJA HOSPITAL, MUMBAI

FORMER RADIOLOGIST AT:

• FORTIS HOSPITAL, NOIDA

• G.T.B HOSPITAL, DELHI

• REGENCY HOSPITAL LTD, KANPUR

• JAWAHAR LAL NEHRU CANCER HOSPITAL, BHOPAL

FMF Certified from

Fetal Medicine Foundation

Reg. No. MP-8932

PATIENT'S NAME : MRS. RANI

AGE/SEX : 24Y/F

REF. BY : DR. PUJA SINGH(MBBS,DGO)

DATE : 24.03.2025

OBSTETRIC USG (EARLY ANOMALY SCAN)

LMP: 22.12.2024

GA(LMP):13wk 1d

EDD : 28.09.2025

- Single live fetus seen in the intrauterine cavity in variable presentation.
- Spontaneous fetal movements are seen. Fetal cardiac activity is regular and normal & is 151 beats /min.
- PLACENTA: is grade I, posterior & not low lying.
- LIQUOR: is adequate for the period of gestation.

Fetal morphology for gestation appears normal.

- Cranial ossification appears normal. Midline falx is seen. Choroid plexuses are seen filling the lateral ventricles. No posterior fossa mass seen. Spine is seen as two lines. Overlying skin appears intact.
- No intrathoracic mass seen. No TR .
- Stomach bubble is seen. Bilateral renal shadows is seen. Anterior abdominal wall appears intact.
- Urinary bladder is seen, appears normal. 3 vessel cord is seen.
- All four limbs with movement are seen. Nasal bone well seen & appears normal. Nuchal translucency measures 1.8 mm (WNL).
- Ductus venosus shows normal flow & spectrum with positive "a" wave (PI ~ 1.05)

FETAL GROWTH PARAMETERS

▪ CRL 69.7 mm ~ 13 wks 1 days of gestation.

- Estimated gestational age is 13 weeks 1 days (+/- 1 week). EDD by USG : 28.09.2025
- Internal os closed. Cervical length is WNL (36.8 mm).
- Baseline screening of both uterine arteries was done with mean PI ~ 1.64(WNL for gestation).

IMPRESSION:

- ± Single, live, intrauterine fetus of 13 weeks 1 days +/- 1 week.
- ± Gross fetal morphology is within normal limits.
- Follow up at 19-22 weeks for target scan for detailed fetal anomaly screening.

Declaration : I have neither detected nor disclosed the sex of the fetus to pregnant woman or to anybody. (It must be noted that detailed fetal anatomy may not always be visible due to technical difficulties related to fetal position, amniotic fluid volume, fetal movements, maternal abdominal wall thickness & tissue ecogenicity. Therefore all fetal anomalies may not be detected in every examination.)
(DR. ANKITA VIJAYVARGIYA)
Patient has been counselled about the capabilities & limitations of this examination.)

Shop No. 22/23, Lower Ground Floor (Basement) C.I. Square Mall, Kolar Road, Bhopal
Mob.:9648844111, 7379330099

Shop No. 22/23, Lower Ground Floor (Basement) C.I. Square Mall, Kolar Road, Bhopal
Mob.:9648844111, 7379330099



First Trimester Screening Report

Maran Rani

Date of birth : 22 February 2001, Examination date: 24 March 2025

Address: hno. 00, suhagpur kolar road
Bhopal
INDIA

Referring doctor: Dr. PUJA SINGH (MBBS , DGO)

Maternal / Pregnancy Characteristics:

Racial origin: South Asian (Indian, Pakistani, Bangladeshi).

Parity: 0.

Maternal weight: 59.0 kg; Height: 157.5 cm.

Smoking in this pregnancy: no; Diabetes Mellitus: no; Chronic hypertension: no; Systemic lupus erythematosus: dont know; Antiphospholipid syndrome: dont know; Patient's mother had preeclampsia: no.

Method of conception: Spontaneous;

Last period: 22 December 2024

EDD by dates: 28 September 2025

First Trimester Ultrasound:

US machine: logiq f6. Visualisation: good.

Gestational age: 13 weeks + 1 days from dates

EDD by scan: 28 September 2025

Findings	Alive fetus	
Fetal heart activity	visualised	
Fetal heart rate	151 bpm	
Crown-rump length (CRL)	69.7 mm	
Nuchal translucency (NT)	1.8 mm	
Ductus Venosus PI	1.050	
Placenta	posterior high	
Amniotic fluid	normal	
Cord	3 vessels	

Chromosomal markers:

Nasal bone: present; Tricuspid Doppler: normal.

Fetal anatomy:

Skull/brain: appears normal; Spine: appears normal; Heart: No TR.; Abdominal wall: appears normal; Stomach: visible; Bladder / Kidneys: visible; Hands: both visible; Feet: both visible.

Uterine artery PI:	1.64	equivalent to 1.050 MoM
Mean Arterial Pressure:	86.4 mmHg	equivalent to 1.040 MoM
Endocervical length:	36.8 mm	

Risks / Counselling:

Patient counselled and consent given.

Operator: DR. ANKITA VIJAYVARGIYA, FMF Id: 204664

Condition	Background risk	Adjusted risk
Trisomy 21	1: 1019	<1: 20000
Trisomy 18	1: 2558	<1: 20000
Trisomy 13	1: 8005	<1: 20000
Preeclampsia before 34 weeks		1: 452

First Trimester Screening Report

Fetal growth restriction before 37 weeks

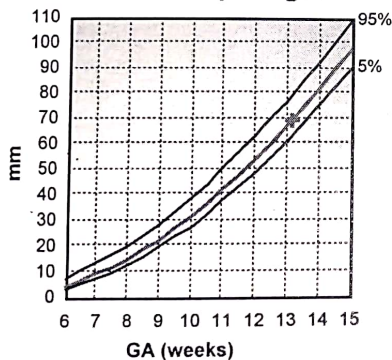
1: 150

The background risk for aneuploidies is based on maternal age (24 years). The adjusted risk is the risk at the time of screening, calculated on the basis of the background risk and ultrasound factors (fetal nuchal translucency thickness, nasal bone, tricuspid Doppler, ductus venosus Doppler, fetal heart rate).

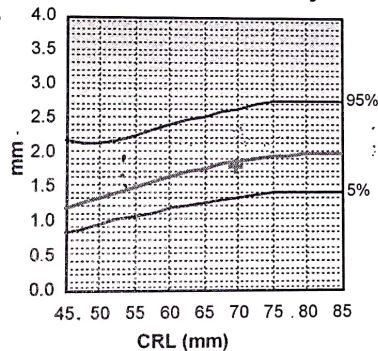
Risks for preeclampsia and fetal growth restriction are based on maternal demographic characteristics, medical and obstetric history, uterine artery Doppler and mean arterial pressure (MAP). The adjusted risk for PE < 34 weeks or the adjusted risk for FGR < 37 weeks is in the top 10% of the population. The patient may benefit from the prophylactic use of aspirin. All biophysical markers are corrected as necessary according to several maternal characteristics including racial origin, weight, height, smoking, method of conception and parity.

The estimated risk is calculated by the FMF-2012 software (version 2.81) and is based on findings from extensive research coordinated by the Fetal Medicine Foundation (UK Registered charity 1037116). The risk is only valid if the ultrasound scan was performed by a sonographer who has been accredited by the Fetal Medicine Foundation and has submitted results for regular audit (see www.fetalmedicine.com).

Crown-rump length



Nuchal translucency



1st trimester risk of Trisomy 21

