

Dr. Neelam Chhajed

Consultant Feto-Maternal Medicine


Reg. No. 2001/02/469, PCPNDT Reg. No. 476

MRCOG, MD DNB (O & G), MBBS

International Masters in fetal Medicine (Barcelona)

FMF UK Certified NT & Doppler Specialist (Id-71536)

Past Ex. North Cumbria University, Hospital (UK)



**NEWLIFE
HOSPITAL**

& FETAL MEDICINE CENTRE

A UNIT OF CHHAIKHEALTHCARE PVT. LTD.

Reg. No. 1031

Patient Name	Mrs. JHANVI MAYUR NAGPAL	Age (yrs)	27 Y/F	D.O.B: 13/09/1997
Referred by	DR. RUPESHRI BHOYAR	Visit date	11/04/2025	
Patient Id	NFMCE10/19415	Equipment	Voluson E10	
LMP	07/01/2025	LMP EDD	14/10/2025	
LMP GA	13W3D	US GA	12W6D	

Early pregnancy (Nuchal Scan) USG report

Real time b mode ultrasonography done via transabdominal route by voluson e10

Indication: NT scan

A single live intrauterine gestation seen with spontaneous movements.

Liquor appears to be adequate for gestation.

Cardiac activity seen with FHR 169 BPM.

Flow across tricuspid valve and Ductus venosus is normal.

Nuchal Translucency measures 1.6 mm and is 40 percentile (which is within normal limits) for this CRL.

Intracranial translucency appears normal. (1.9 mm)

Nasal bone seen measuring 3.4 mm (50.0 %tile)

Bladder and stomach bubble seen.

All four limbs with spontaneous movement seen.

Spine, facial skeleton forming. Midline falx seen

Placenta forming – Anteriorly, 1.20 cm from os .

No evidence of any sub chorionic collection at present.

Cervical length appears normal and measures 4.02 cm (os closed.)TVS

Uterine Artery Doppler (Pulsatility index)

Right Uterine Artery PI	Left Uterine Artery PI	Mean uterine artery PI:
1.33	2.30	1.82
Corresponding to : 74 th Percentile which is within normal limits.		

(Ref percentiles: fetal medicine Barcelona)

253, Canal Road, Near Sewakunj Agrawal Bichayat Kendra, Giripeth, Nagpur-440 010

0712 - 3554990 Mob : 86683 62579,

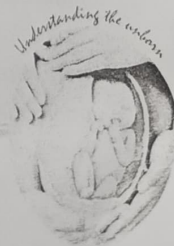www.nagpurfetalmedicinecentre.com,

Timing

Mor. 9.30 am to Eve. 6.00 pm (Sunday Closed)

Email

newlifeclinic15@gmail.com



Fetal Biometry

PARAMETER	MEASUREMENTS(cm)	GESTATIONAL AGE
B.P.D.	2.01	13W1D
AC	5.87	12W5D
F.L.	0.87	12W4D
C.R.L	6.62	12W6D


Impression:

Single live intrauterine gestation corresponding to average Gestational age of 12W6D with Nuchal translucency of 1.6 mm

Estimated fetal weight as per BPD, AC& FL is approximately 62+/-9g

Ultrasound age and gestational age of fetus corresponding hence EDD assigned as per LMP

(Detailed Anomaly scan suggested @ 18-20 weeks)


Dr. Neelam Chhajer

Consultant fetal medicine

Many thanks for the referral.

Declaration of doctor/person conducting ultrasonography/image scanning.

I, **Dr. Neelam Chhajer**, declare that while conducting ultrasonography, I have neither detected nor disclosed the sex of the fetus to anybody in any manner.

(P.S It must be noted that detailed feta anatomy may not always be clear due to technical difficulties related to advanced gestational age, feta position, reduced liquor, maternal abdominal wall thickness fetal movements etc. therefore all fetal anomalies may not be detected, also kindly note that ear and digits examination is not a routine part of this exam, also kindly note that anomalies like isolated anal atresia may not be picked up on scan due to limitation of imaging these organs.)

