

## Dr. Neelam Chhajer

Consultant Feto-Maternal Medicine

Reg. No. 2001/02/469, PCPNDT Reg. No. 476

MRCOG, MD DNB (O & G), MBBS

International Masters in fetal Medicine (Barcelona)

FMF UK Certified NT & Doppler Specialist (Id-71536)

Past Ex. North Cumbria University, Hospital (UK)



**NEWLIFE  
HOSPITAL**  
& FETAL MEDICINE CENTRE  
A UNIT OF CHHAJED HEALTHCARE PVT LTD.  
Reg. No. 1031

Patient Name	Mrs. ROSHNI RASIK KUWARE	Age (yrs)	32 Y/F	D.O.B: 20/03/1993
Referred by	DR. VIJAYKUMAR WANVE	Visit date	14/04/2025	
Patient Id	NFMCE10/19447	Equipment	Voluson E10	
LMP	24/01/2025	LMP EDD	31/10/2025	
LMP GA	11W3D	US GA	12W2D	

### Early pregnancy (Nuchal Scan) USG report

Real time b mode ultrasonography done via transabdominal route by voluson e10

#### Indication: NT scan

A single live intrauterine gestation seen with spontaneous movements.

Liquor appears to be adequate for gestation.

Cardiac activity seen with FHR 170 BPM.

Flow across tricuspid valve and Ductus venosus is normal.

**Nuchal Translucency measures 2.2 mm and is 86 percentile (which is within normal limits) for this CRL.**

Intracranial translucency appears normal. (1.7 mm)

**Nasal bone seen measuring 2.5 mm ( 49.0 %tile), however it is appearing less echogenic compared to overlying skin ?? unossified.**

Bladder and stomach bubble seen.

All four limbs with spontaneous movement seen.

Spine, facial skeleton forming. Midline falx seen

Placenta forming - Posteriorly, 3.36 cm from os

No evidence of any sub chorionic collection at present.

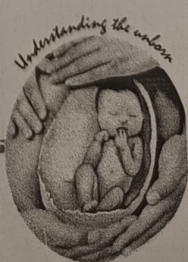Cervical length appears normal and measures 3.26 cm (os closed.) Transabdominal

#### Uterine Artery Doppler (Pulsatility index)

Right Uterine Artery PI	Left Uterine Artery PI	Mean uterine artery PI:
1.93	1.69	1.81
Corresponding to : 56 <sup>th</sup> Percentile which is within normal limits.		

(Ref percentiles: fetal medicine Barcelona)

Address : 253, Canal Road, Near Sewakunj Agrawal Bichayat Kendra, Giripeth, Nagpur-440 010  
Tel : 0712 - 3554990 Mob : 86683 62579, Timing : Mor. 9.30 am to Eve. 6.00 pm (Sunday Closed)  
Web : www.nagpurfetalmedicinecentre.com, Email : newlifeclinic15@gmail.com





### Fetal Biometry

PARAMETER	MEASUREMENTS(cm)	GESTATIONAL AGE
B.P.D.	1.84	12W6D
AC	5.39	12W2D
F.L.	0.78	12W3D
C.R.L	5.77	12W2D

### Impression:


Single live intrauterine gestation corresponding to average Gestational age of 13W0D with Nuchal translucency of 2.2 mm.

In view of NT being on higher centile and ?? unossified nasal bone, NIPT would be recommended.

Estimated fetal weight as per BPD, AC& FL is approximately 57+/-8g

Ultrasound age and gestational age of fetus corresponding hence EDD assigned as per LMP

(Detailed Anomaly scan suggested @ 18-20 weeks)

  
**Dr. Neelam Chhajed**  
Consultant fetal medicine

**Many thanks for the referral.**

### Declaration of doctor/person conducting ultrasonography/image scanning.

I, **Dr. Neelam Chhajed**, declare that while conducting ultrasonography, I have neither detected nor disclosed the sex of the fetus to anybody in any manner.

*(P.S It must be noted that detailed feta anatomy may not always be clear due to technical difficulties related to advanced gestational age, feta position, reduced liquor, maternal abdominal wall thickness fetal movements etc. therefore all fetal anomalies may not be detected, also kindly note that ear and digits examination is not a routine part of this exam, also kindly note that anomalies like isolated anal atresia may not be picked up on scan due to limitation of imaging these organs.)*

