



Established in 1969 by
Kasturba Health Society

Department of Radiodiagnosis
Mahatma Gandhi Institute of Medical Sciences

Sevagram | Wardha | Maharashtra | 442 102 | India
Phone: +91 7152 284374 to 284355 Ext. - 289

Laboratory : ULTRASONOGRAPHY

Patient ID : 202007034369
Name : Nancy Jivan Patel
Age/Gender : 33 Years/Female
Department : Obs and Gynae/UNIT 1

Patient Type : OPD
Scan Date : 29-Apr-2025
Accession No : 181520250012528

USG OBSTETRICS

Findings:

LMP 01/02/2025

EDD by LMP 08/11/2025

GA by LMP 12 wks/ 3 days

Gravid uterus shows evidence of single intrauterine gestational sac with single fetus

MEASUREMENTS AND GESTATION AGE

Indices Measurements (mm)

C R L 64.1 mm

Est. Fetal age

12 wks/ 6 days

Est. Fetal age 12 wks/ 6 days

Approx EDD 05/11/2025

Foetal Heart Rate 157 bpm

Nasal bone seen

Nuchal translucency- 1.2 mm

PLACENTA

Location Posterior Lower segment free

Maturity Grade 0

Ductus venosus waveform appears normal.

Right Ovary- Size: 2.8 x 1.4 cm, Normal in morphology and echotexture

Left Ovary- Size: 2.6 x 1.9 cm, Normal in morphology and echotexture

Cervix - 4.2 cm, Internal os closed.

Impression: USG Obstetrics reveals-

Single intrauterine live fetus with mean gestational age 12-13 wks.

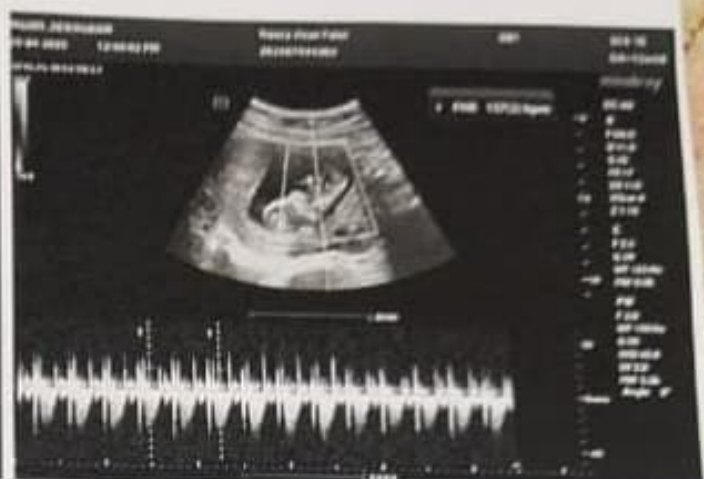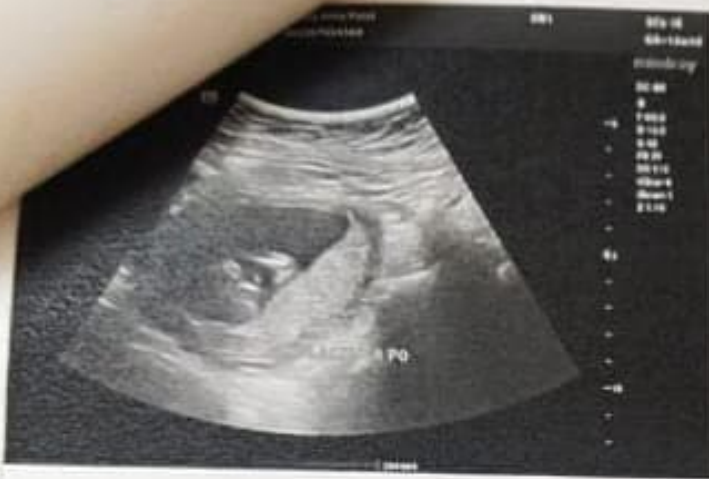Suggested follow up at 20-22 wks for anomaly scan.

Declaration Of Doctor :

I Dr. Sachin Dawale, declare that while conducting ultrasonography on Mrs. Nancy Jivan Patel, I have neither detected nor disclosed the sex of her foetus to anybody in any manner.

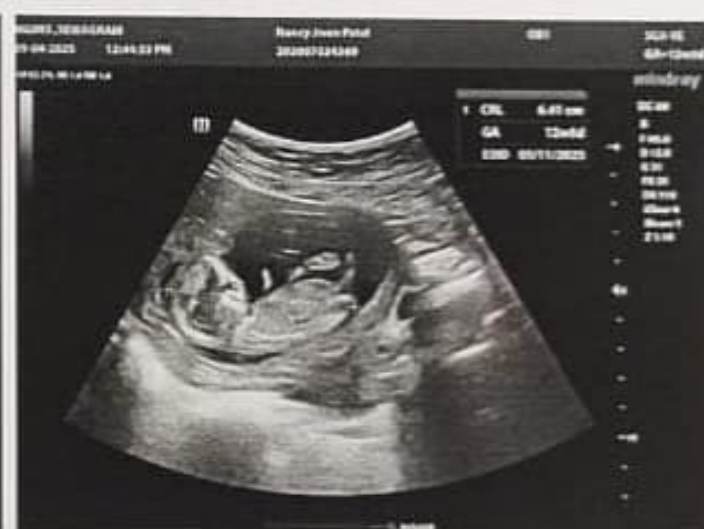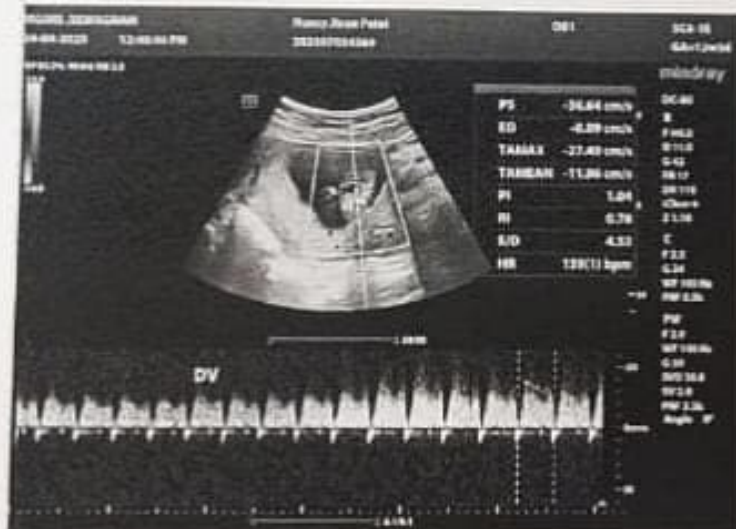
29-Apr-2025

Reported By: Dr. Sachin Dawale
Resident Radiology



U.S.G OBSTETRICS

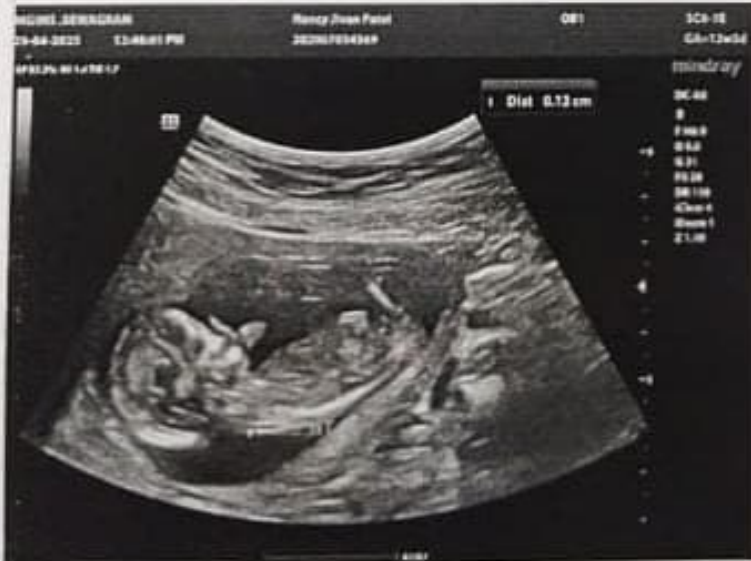U.S.G OBSTETRICS



U.S.G OBSTETRICS

U.S.G OBSTETRICS

20m



U.S.G OBSTETRICS