

Patient name	Mrs. PRANALI RUTWIK NAIGAONKAR	Age/Sex	34 Years / Female
Patient ID	D24533	Visit No	1
Referred by	Dr. ARTI KABRA MURKEY	Visit Date	08/05/2025
LMP Date	18/12/2024 LMP EDD: 24/09/2025[20W 1D]		

## OB - 2/3 Trimester Scan Report

### Indication(s)

#### SECOND TRIMESTER ANOMALY SCAN

Real time B-mode ultrasonography of gravid uterus done.

Route: Transabdominal

Single intrauterine gestation

### Maternal

Cervix measured 3.20 cms in length.

Right uterine PI : 1.65.

Left uterine PI : 1.1.

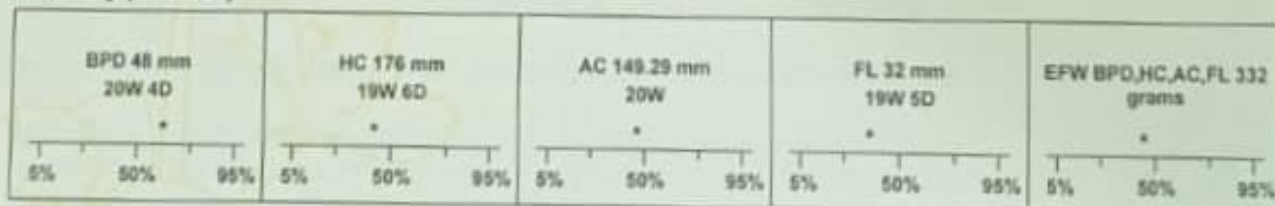
Mean PI : 1.38 (75%ile)

### Fetus

#### Survey

- Presentation : Variable
- Placenta : Posterior not low lying
- Liquor : Normal
- Umbilical cord : Two arteries and one vein
- Fetal activity : Fetal activity present
- Cardiac activity : Cardiac activity present
- Fetal heart rate - 142 bpm

### Biometry (Hadlock)



Foot Length : 33 mm

TCD : 21 mm

### Aneuploidy Markers

Nasal Bone : seen

Nuchal Fold : Normal

### Fetal Anatomy

#### Head

Head - Midline falx seen. Both lateral ventricles appeared normal.

Posterior fossa appeared normal. No identifiable intracranial lesion seen.

#### Spine

Spine appeared normal. No evidence of significant open neural tube defect

**Mrs. PRANALI RUTWIK NAIGAONKAR / D24533 / 08/05/2025 / Visit No 1**

**Face**

Fetal face seen in the coronal and profile views.  
 Both orbits, nose and mouth appeared normal

**Thorax**

Both lungs seen. No evidence of pleural or pericardial effusion.  
 No evidence of SOL in the thorax.

**Heart**

Heart appears in the mid position. Normal cardiac situs.  
 Four chamber view appeared normal. Outflow tracts appeared normal.

**Abdomen**

Abdominal situs appeared normal. Stomach and bowel appeared normal.  
 Normal bowel pattern appropriate for the gestation seen.  
 No evidence of ascites. Abdominal wall intact.

**KUB**

Right and Left kidneys appeared normal.  
 Bladder appeared normal

**Extremities**

All fetal long bones visualized and appear normal for the period of gestation.  
 Both feet appeared normal

**Impression**

SINGLE GESTATION CORRESPONDING TO A GESTATIONAL AGE OF 20 WEEKS 1 DAY  
 GESTATIONAL AGE ASSIGNED AS PER LMP  
 PLACENTA - POSTERIOR NOT LOW LYING  
 PRESENTATION - VARIABLE  
 LIQUOR - NORMAL  
 ESTIMATED FETAL WEIGHT ACCORDING TO BPD, HC, AC, FL :- 332 + / - 33.2 GMS.

THE FETUS APPEARS STRUCTURALLY NORMAL FOR THE PERIOD OF GESTATION.

MATERNAL - RIGHT UTERINE ARTERY SHOWS INCREASED RESISTANCE TO FLOW  
 SUGGESTED REPEAT SCAN AFTER 8 WEEKS FOR INTERVAL GROWTH AND FETAL DOPPLER.  
 (Please bring referral letter.)

I Mrs. Pranali Naigaonkar Declare that while undergoing Ultrasonography, I do not want to know the sex of my fetus.  
**DECLARATION** - I declare that while conducting ultrasonography / image scanning, I have neither detected nor disclosed the sex of the fetus to anybody in any manner. All congenital anomalies and genetic conditions may not be detected on ultrasonography due to limitations like fetal position, amount of liquor, previous scars, Small VSDs, late appearance of few anomalies, TO fistula and structures that are not part of routine imaging protocol. Detailed fetal echo not included in this scan.

**DR. JAGRUTI BHUSHAN MURKEY**  
 DNB (OBS & GYN), DGO, MBBS  
 FETAL MEDICINE SPECIALIST  
 REG. NO. 2007 / 06 / 2480  
 DAFFODILS Mudholkar Peth, Amravati (M.S.)

DR JAGRUTI MURKEY DNB DGO MBBS  
 CONSULTANT FETAL MEDICINE SPECIALIST