

Section 'D'

## DECLARATION OF THE PERSON UNDERGOING PRENATAL DIAGNOSTIC TEST / PROCEDURE

I, Rida Rauf ali Khan

असे घोषित करते की अल्ट्रा-सोनोग्राफी/प्रतिमा स्कॅनिंग करुन मी माझ्या गर्भाचे लिंग जाणून घेऊ इच्छित नाही  
/declare that undergoing Prenatal Diagnostic Test/Procedure. I do not want to know the sex of my foetus.

Date :

23/05/2025

गरोदर स्त्रीची सही/अंगठ्याचा ठसा. Rida Signature/Thumb impression of the  
person undergoing the Prenatal Diagnostic Test/Procedure

In case of thumb impression

Identified by (Name) : \_\_\_\_\_

Age : \_\_\_\_\_

Sex : \_\_\_\_\_

Relation (If any) : \_\_\_\_\_

Address & Contact No. : \_\_\_\_\_

Signature of a person attesting thumb Impression : \_\_\_\_\_

Date : \_\_\_\_\_

## DECLARATION OF DOCTOR

I, Dr. Kalpana S munde

declare that while conduting ultrasonography / image scanning on

Rida Rauf ali Khan

I have neither detected nor disclosed the sex of her fetus to

anybody in any manner \_\_\_\_\_

Date :

23/05/2025

Dr. Kalpana S. Munde  
MD Radiodiagnosis  
Reg. No. 2010/07/2406



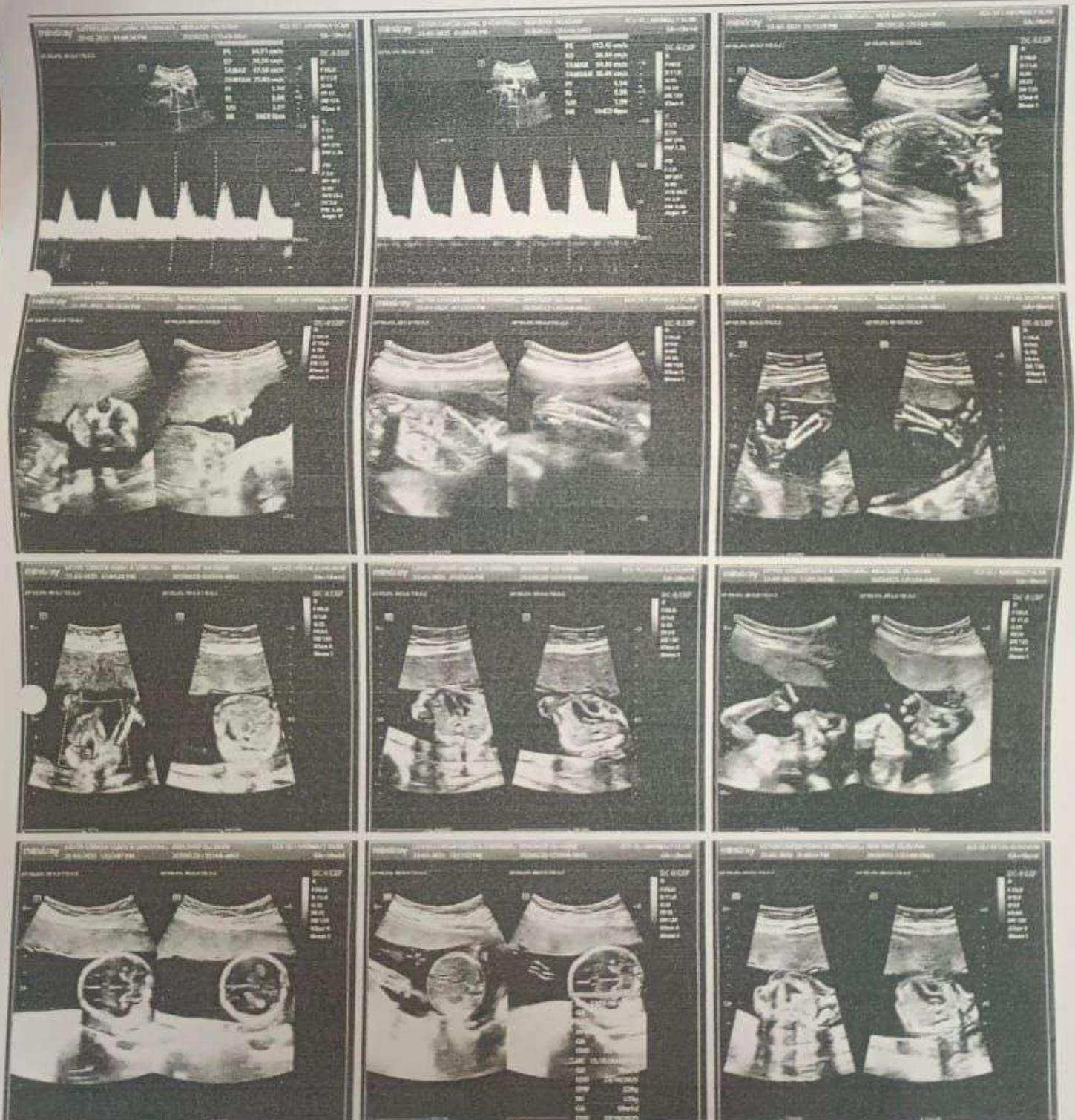


# FUS CANCER CLINIC AND SONOGRAPHY CENTER

Door, Simant Mangal Karayalaya, Opp Devgiri Bank, Near Khinvasara Multiplex, Aurangpura  
Aurangabad - 431001

Name: Mrs. RIDA RAUF ALI KHAN  
Age: 25 Y  
Sex: F  
Date: 23-May-2025

Ref By: Dr. TAHZEEB KHAN  
Study: USG ANOMALY SCAN  
Examined By: Dr. Kalpana S Munde  
MD Radiodiagnosis





aphy  
Doppler  
A Scan

Simant Mangal Karyalaya, Opp. Devgiri Nagri Bank, Near Khinvasara Multiplex(Amba-Apsara), Aurangpura, Aurangabad - 431001.

Name: Mrs. RIDA RAUF ALI KHAN  
Age: 25 Y  
Sex: F  
Date: 23-May-2025

Ref By: Dr. TAHZEEB KHAN  
Study: USG ANOMALY SCAN  
Examined By: Dr. Kalpana S Munde  
MD Radiodiagnosis

**Fetal Skeletal System:**

The vertebral column is well seen and appears normal.  
Both upper limbs are seen and appear normal.  
Both lower limbs are seen and appear normal.

**Fetal Parameters:**

BPD measures 4.0 cm corresponding to 18 weeks and 2 days.  
HC measures 15.1 cm corresponding to 18 weeks and 1 days.  
AC measures 12.7 cm corresponding to 18 weeks and 2 days.  
FL measures 2.6 cm corresponding to 18 weeks and 1 days.  
EFW: 229 grams (+/- 33 grams)  
EDD by USG-23/10/2025

Blood vessels	RI	PI	S/D
Right uterine artery	0.5	0.9	1.9
Left uterine artery	0.6	1.1	2.9

**Maternal Survey:**

Cervical length measures 35 mm.  
Internal os closed.  
No obvious adnexal pathology is seen.

*(Not all abnormalities are detected on ultrasonography)*

**IMPRESSION:** Single live fetus of 18 weeks & 1 days of gestation (gestational age assigned as per fetal biometry) with no obvious congenital anomaly in present scan.

Needs follow up after 3 weeks for heart and face.

  
Dr. Kalpana S Munde  
Womens Imaging Specialist  
MD Radiodiagnosis

raphy  
Doppler  
al Scan



CANCER CLINIC & SONOGRAPHY CENTER

95991 48563 Kalpanaghuge9@gmail.com

Simant Mangal Karyalaya, Opp. Devgiri Nagri Bank, Near Khinvasara Multiplex(Amba-Apsara), Aurangpura, Aurangabad - 431001.

Name: Mrs. RIDA RAUF ALI KHAN  
Age: 25 Y  
Sex: F  
Date: 23-May-2025

Ref By: Dr. TAHZEEB KHAN  
Study: USG ANOMALY SCAN  
Examined By: Dr. Kalpana S Munde  
MD Radiodiagnosis

### ANOMALY SCAN

LMP: 16/01/2025 ( 18 Weeks 1 days)    LMP EDD: 23/10/2025

#### General Survey:

There is single live fetus seen in changing presentation and changing lie.  
Cardiac activity is present.  
Fetal movements are well appreciated.  
Placenta is anteriorly seen.  
Amniotic fluid is normal.

#### Fetal Head:

The cerebellum and cistern magna are well seen and appear normal.  
Lateral ventricle diameter measures 5 mm.

#### Fetal Face:

Fetal face is well seen and appears normal.  
Both orbits are seen and appear normal.  
Both lips and nasal bones are seen and appear normal.

#### Fetal Thorax:

Fetal heart appears normal in size and position.  
FHR measures 136 bpm and show regular rhythm.  
The interventricular septum is normal.  
Both outflow tracts are seen and appear normal.  
Both lungs are well seen and appear normal.  
The diaphragm is well seen and appears normal.

#### Fetal Abdomen:

The anterior abdominal wall is intact.  
The stomach bubble is well seen and appears normal.  
Both kidneys are seen and appear normal.  
The liver and visualized bowel loops appear normal.  
Urinary bladder is well seen and appears normal.  
Three vessels cord seen.

P.T.O.

Dr. Kalpana S Munde  
Womens Imaging Specialist  
MD Radiodiagnosis