



RAJ DIAGNOSTIC CENTRE (Since 1994)

SAGAR

*DIGITAL X-RAY * SONOGRAPHY * COLOUR DOPPLERS*
SMALL PARTS USG TARGET/ANOMALY SCAN*NT SCAN*

* RAJ DIAGNOSTIC CENTRE,
MAHAVEER MARKET, GOUR MURTI,
SAGAR, M.P. 470 002
TEL-07582 244966

* RAJ DIAGNOSTIC CENTRE,
BALAK COMPLEX MARKET,
MEDICAL COLLEGE ROAD, SAGAR, M.P. 470 001
TEL-07582 356492, Mail us at rajsonography@gmail.com

Name-Smt KALYANI

Ref by Dr. SAVITA VISHWAKARMA (GYN)

Date-23/06/25

ROUTINE USG REPORT OF GRAVID UTERUS (GROWTH SCAN)

- Single live fetus with cephalic Presentation seen in the uterine cavity .
- Fetal heart beats visualised & recorded on M. mode- regular F.H.R 148 beats/minutes.
- Fetal movements are normal .
- Fetal parameters :-

BPD	4.2 cm
HC	16.2 cm
AC	14.0 cm
FL	3.2 cm
- Fetal weight as estimated comes out to be approx 305 \pm 16 %.
- Placenta is anterior in position , does not reach to O.S.
- Maturity is grade - I
- Liquor is adequate .

IMPRESSION:

- Single live intrauterine pregnancy of mean gestational age of 20.3 weeks \pm 1 week noted with cephalic presentation

EDD BY PREVIOUS USG -07/11/25

Thanks For Ref.

During conducting the sonography I have neither detected nor disclosed the sex of fetus to anybody in any manner .

Dr. Raj Singhai (Reg No-MP 19898/ FMF (UK) ID-273503)
MBBS (Nagpur), DMRE (Mumbai), NT Certification (FMF-UK),
Fetal Medicine Imaging Fellow (Barcelona)
Consultant Radiologist

Dr. Rajendra Jain (Reg No-MP 8093)
MBBS, DMRE
Consultant Radiologist

This is only a professional opinion and not the diagnosis. Findings should be co-related clinically # Not for medico legal purposes.

"Equipped with latest GE Voluson S8 Touch & GE Logiq P7 3D/4D ultrasound system"



RAJ DIAGNOSTIC CENTRE (Since 1994)

SAGAR

*DIGITAL X-RAY * SONOGRAPHY * COLOUR DOPPLERS*
*SMALL PARTS USG * TARGET/ANOMALY SCAN*NT SCAN*

"We have a vision"

* RAJ DIAGNOSTIC CENTRE,
MAHAVEER MARKET, GOUR MURTI,
SAGAR, M.P, 470 002
TEL-07582 244966

* RAJ DIAGNOSTIC CENTRE,
BALAK COMPLEX MARKET,
MEDICAL COLLEGE ROAD, SAGAR, M.P, 470 001
TEL-07582 356492, Mail us at rajsonography@gmail.com

URINARY TRACT :

Both kidneys appear normal in size . No pelvicalyceal dilatation .
Urinary bladder appears normal .

LIMBS :

All the four limbs are seen . The long bones appear normal for the period of gestation .
Both the hands and feet appeared normal .

UMBILICAL CORD :

Cord appears normal (3 vessel cord) and reveals two arteries and one vein .
Central cord insertion noted.

MATERNAL CERVIX- Internal Os is closed with cervical length – 4.4 cm

ANTENATAL SOFT MARKERS-

FETAL VENTRICULOMEGALY- NO	ECHOGENIC BOWEL- NO
ECHOGENIC INTRACARDIAC FOCUS (EIF)- NO	SINGLE UMBILICAL ARTERY- NO
CHOROID PLEXUS CYSTS- NO	FETAL PYLECTASIS- NO

(Antenatal soft markers are fetal sonographic findings that are generally not abnormalities as such but are indicative of an increased age adjusted risk of an underlying fetal aneuploidic or some non chromosomal abnormalities.)

Opinion : No sonographic fetal anomalies detected at present for this gestational age .

- Note- 1) Finger counting & ears evaluation is not done in this scan due to technical difficulties .
2) Fetal echo is advised separately to rule out cardiac anomalies at 22-24 weeks
3) Detection of most but not all the congenital fetal anomalies is always possible due to suboptimal scanning because of fetal & maternal factors such as liquor volume, gestational age, fetal position and movement, maternal abdominal wall thickness.
4) Some defects/anomalies may appear late in pregnancy which might not be detected in this anomaly scan.

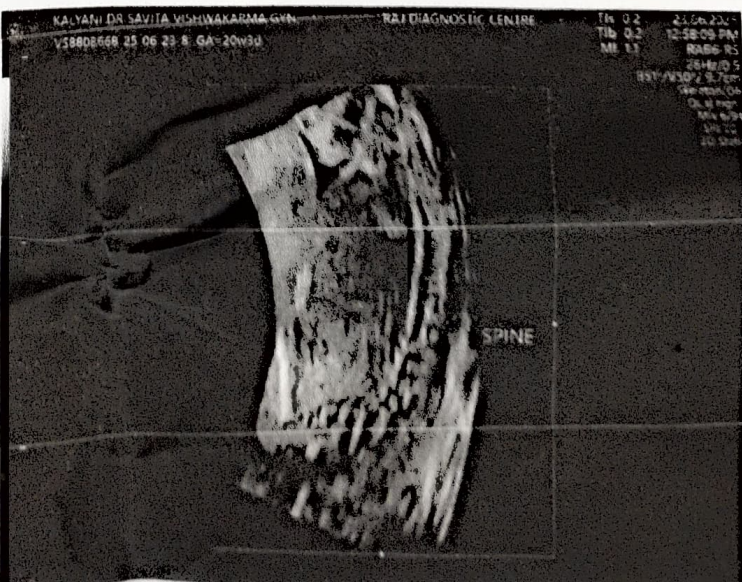
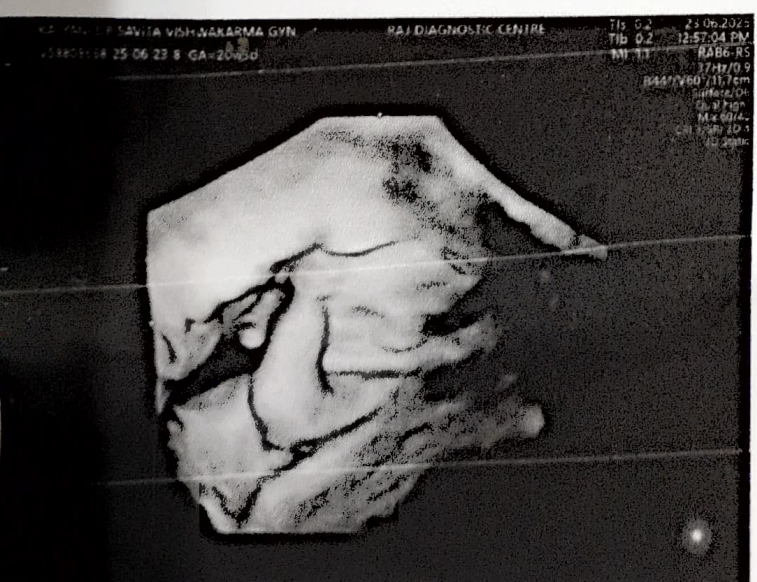
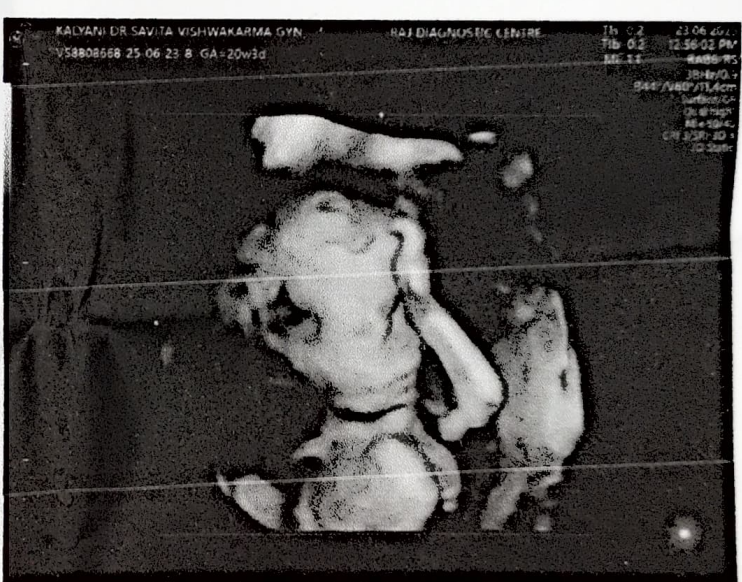
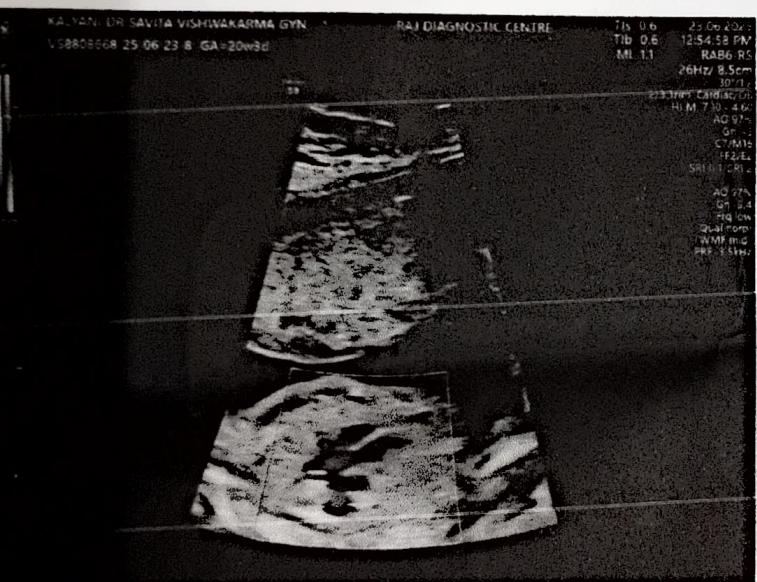
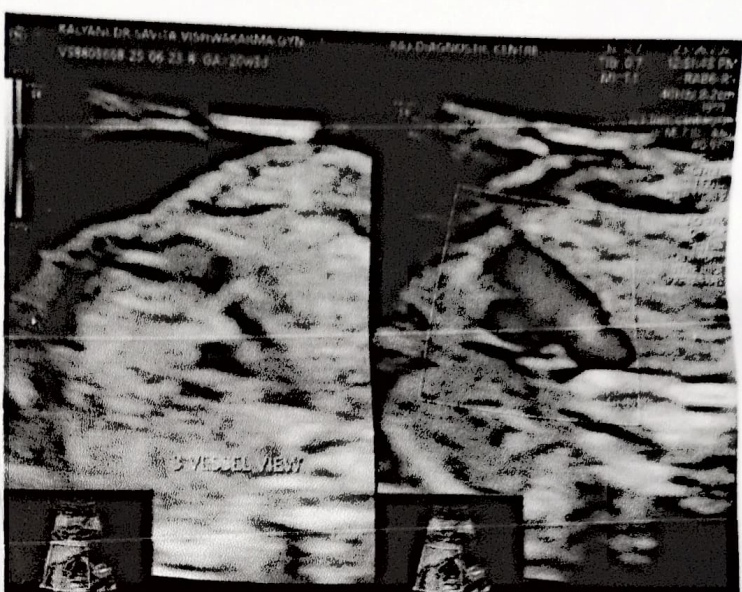
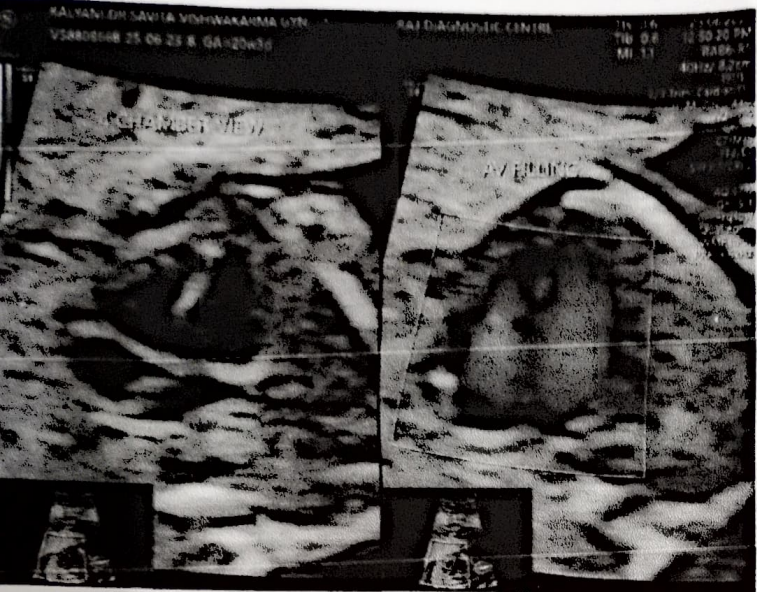
Adv- Co-relation with history, maternal age and maternal serological results.

Dr. Raj Singhai (Reg No-MP 19898/ FMF (UK) ID-273503)
MBBS (Nagpur), DMRE (Mumbai), NT Certification (FMF-UK),
Fetal Medicine Imaging Fellow (Barcelona)
Consultant Radiologist

Dr. Rajendra Jain (Reg No-MP 8093)
MBBS, DMRE

Consultant Radiologist

This is only a professional opinion and not the diagnosis. Findings should be co-related clinically & Not for medical
"Equipped with latest GE Voluson S8 Touch & GE Luminia P7 HD"





धनु श्री क्लीनिक

डॉ. सविता विश्वकर्मा
मो. 9171852870

Date: 15/03/25

Pt. Name: Mrs. Kalyani Chauhan

110 Haidapur

R
X

Age / Sex: 24 y. / F Weight:

1P: 26/1/05

40

30 days overdue / opt +ve

OH:-

P, L

2: 08/10/05

Nausea, vomiting

8y y fcu F1ND

CP to Laben DH

- 120/80 mm Hg

- nb. Rabyant 20

100 x 100

- nb. Grammel MD

छादा हल्दी के टोने पर

- nb. Genset forte

- Gyp. Lyodis forte

amp 100 x 100 mm

- Biochem powder

amp in water

दवाईयाँ डॉक्टर को दिखाकर प्रयोग करें ।

पता - हनुमान बाग, क्षमा हार्डवेयर वाली गली, आरती मेडिकल के सामने, बेगमगंज, जिला-रायसेन

23/6/25

SLUF of 20.3 wks

2 xpp

- 305

- grade 7

- 11/1/25

- 148/bpm

Adn
Quadruple
marker

11/1/25



भारत सरकार

Government of India



Issue Date: 07/05/2014



कल्याणी कौशिक

Kalyani Koushik

जन्म तिथि/DOB: 20/07/2000

महिला/ FEMALE

5680 7473 3896

VID : 9127 2758 1646 6331

मेरा आधार, मेरी पहचान