

जगदाळे मामा हॉस्पिटल, बारशी

डॉ. वैभव मोराळे

एम.बी.बी.एस.एम.एस. (जनरल सर्जन)

फेलोशिप इन मिनेरल अँसेस सर्जरी

जनरल व लॅप्रोस्कोपीक सर्जन

रजि.नं. 2011/04/0860

वेळ:- स.10.00 ते 1.00, सायं.6.00 ते 8.00



* कन्सल्टिंग *

डॉ.मोराळे क्लिनिक,

भगवंत मंदिराशेजारी, कचेरी रोड, बारशी.

O.P.D. वेळ : दुपारी 1 ते 6

पोटाचे विकार, जनरल सर्जरी, लॅप्रोस्कोपी, एन्डोस्कोपी, पाईल्स

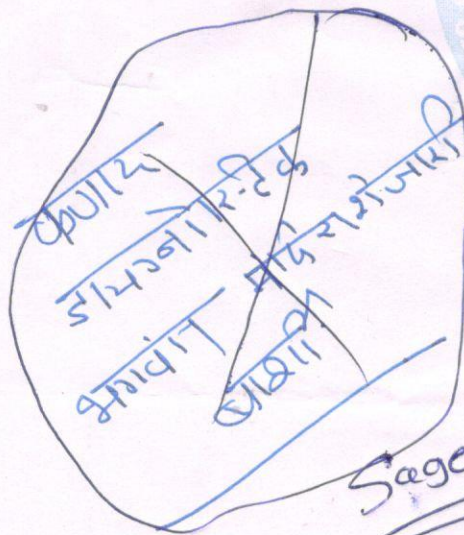
नाव Mukund Tape दिनांक 9/7/20

पत्ता Dr. Morale Sir. वय 45/M लिंग Male वजन 70

Rx

B2908712 do acute calculus cholelithiasis

Lap. choleystectomy done



Sage Lab

दिनांक..... रक्ताचे नांव.....

फार्मासिस्टचे नांव व पत्ता.....



SHRI MAHALAXMI

SONOGRAPHY AND XRAY CLINIC

Dr. Shripad Shivajirao Nandurkar

MBBS, MD Radiodiagnosis

Fetal Medicine Foundation Certified (UK)

ISCU Certified Fellow In Echocardiography

NAME: MR. MUKUND TUPE

AGE/SEX: 46 YEARS/ MALE

REF: DR. PUSHKARAJ YADAV MS, DNB URO

DATE: 30-06-25

USG ABDOMEN & PELVIS

Liver is normal in size measuring 15 cm with normal echotexture. No focal lesion seen.

Intrahepatic biliary radicals not dilated. CBD is normal.

Portal vein is normal in size and shows normal hepatopetal flow with maintain respiratory phasicity.

IVC and AORTA are normal in size and shows normal flow.

Gall bladder is over distended and shows thickened oedematous wall with diffuse echoes.

Multiple calculi (approx. 5 in number) of avg size 5-10 mm seen in neck of gall bladder.

Wall thickness measures 4.5 mm.

Probe tenderness present --Sonographic murphy sign is positive.

Pancreas appears normal in size, shape and echopattern. No focal lesion seen.

Spleen is normal in size measuring 9 cm with normal echopattern. No focal lesion seen. splenic vein is normal.

Right kidney measures 9.6 x 4.4 cm and is normal in size shape, position.

Cortical thickness and cortico-medullary junction is normal.

No calculus seen. No hydronephrosis seen.

Left kidney measures 9.1 x 4.7 cm and is normal in size shape, position.

Cortical thickness and cortico-medullary junction is normal.

No calculus seen. No hydronephrosis seen.

Urinary bladder is well distended & shows normal wall thickness with clear contents. No calculus seen.

Prostate is normal in size, shape and echopattern. Echotextures is normal. No e/o focal lesion.

Bowel shows normal peristalsis. No abnormal bowel dilatation or wall thickening is seen.

No e/o free fluid in abdomen or pelvis. No lymphadenopathy noted.

IMPRESSION:

Gall bladder is over distended and shows thickened oedematous wall with diffuse echoes.

Multiple calculi (approx. 5 in number) of avg size 5-10 mm seen in neck of gall bladder.

Wall thickness measures 4.5 mm.

Probe tenderness present --Sonographic murphy sign is positive.

Features s/o acute calculus cholecystitis.

Bilateral kidneys normal. No calculus/ hydronephrosis seen.

Clinical correlation/SOS follow up suggested.

Thanks for the kind referral.

DR SHRIPAD S NANDURKAR

Consultant radiologist

Reg no-2007/12/4129

Fetal Medicine Foundation ID-215635