





L. N. MEDICAL COLLEGE & J. K. HOSPITAL

(A MCI APPROVED / ISO 9001:2008 CERTIFIED INSTITUTE)



Biometry weight parameter (Hadlock)

BPD 44.7 mm	HC 171.2 mm	AC 154.3 mm	FL - 35.4 mm	EFW BPD,HC,AC,FL
19 W 4 D 41.4%	19 w 5 D 42%	20 w 4 D 74.2%	21 W 1 D 88.1%	372 Grams + 54 Grams.
				91.7%

FETAL BIOMETRIC PARAMETERS

Biometry	measurement(mm)	Weeks	Days	Centile
TCD :	21.1	20	0	79.1%
OOD	30.1	19	3	22.2%
IOD	11.8	18	5	46.9%
Humerus	32.7	21	0	91.1%
Radius	27.9	20	3	63.4%
Ulna	33.2	22	6	97.8%
Tibia	31.2	21	4	95.2%
Fibula	31	21	0	77.7%
Foot	34.1			83.5%
FL-FOOT RATIO	1.04			
HC/AC	1.11			
FL/BPD	79.19%			
FL/AC	22.94%			
NASAL BONE: 6.9 mm (99.50%)		NUCHAL FOLD THICKNESS: 4.9 mm		Cistern Magna: 3.8 mm

2 nd Trimester aneuploidy risk table/Genetic Sonogram:

2 nd Trimester Aneuploidy Markers		
Sr No	Marker	Result
1	Intracardiac Echogenic Focus	Absent
2	Ventriculomegaly	Absent
3	Increased Nuchal Fold	Absent
4	Echogenic Bowel	Absent
5	Mild Hydronephrosis	Absent
6	Short Humerus	Absent
7	Short Femur	Absent
8	Aberrant Right Subclavian Artery	Absent
9	Absent or Hypoplastic Nasal Bone	Normal size
Apriori Risk (From Maternal Age):		1 in 830
LR Ratio:		0.13
Trisomy21 Risk:		1 in 6377



L.N. MEDICAL COLLEGE & J.K. HOSPITAL

(A MCI APPROVED / ISO 9001:2008 CERTIFIED INSTITUTE)



IMPRESSION :

- SINGLE LIVE INTRAUTERINE GESTATION
- ESTIMATED GESTATIONAL AGE BY FETAL BIOMETRY : 20 WEEKS 0 DAYS +/- 1 WEEK
- AGREED EDD (BASED ON LMP): 06/12/2025
- NO OBVIOUS STRUCTURAL CONGENITAL ABNORMALITIES DETECTED FOR GESTATION.
- NO OBVIOUS SONOGRAPHIC MARKERS FOR CHROMOSOMAL ABNORMALITIES NOTED AT THIS GESTATION.
- PLACENTAL: Anterior (1st Away from The Internal-OS)
- CERVICAL LENGTH: 37.2 mm : NORMAL(ON TAS)
- UTERINE ARTERY DOPPLER: SCREEN NEGATIVE FOR PET.

COMMENTS:

- On today's detailed scan, there are no obvious structural abnormalities or markers of chromosomal abnormalities seen. I have explained sonographic findings to the couple in detail.
- I have explained to couple in detail that chromosomal abnormalities can not be diagnosed by ultrasound or blood test on their own. The only way to know the chromosomal make up of the fetus is by karyotyping from amniocentesis including 0.1% chance of procedure related miscarriage.

Suggested Recscan at 26-28 week for Periodic assessment , to rule out evolving anomalies & for growth interval monitoring.

Please note: All abnormalities and genetic syndromes cannot be ruled out by ultrasound examination. Ultrasound examination has its own limitations. Some abnormalities evolve as the gestation advances. The detection rate of abnormality depends on gestational age of the fetus, fetal position, tissue penetration of sound waves, amniotic fluid volume, fetal movement and patients body habitus. Patient has been counselled about the capability & limitation of the examination.

Declaration: I, Dr Sonam Verma declare that while conducting ultrasonography /image scanning on Mrs. Poojitha Verma's Pregnancy, I have neither detected nor disclosed the sex of her fetus to anybody in any manner.

Best Wishes

Dr. Sonam Verma
M.D. RADIOLOGICAL
FETAL MEDICINE CONSULTANT
Reg NO: 18797, FNF ID: 277360

Dr. Sonam Verma
M.D. RADIOLOGICAL
FETAL MEDICINE CONSULTANT
J.K. HOSPITAL
L.N. MEDICAL COLLEGE & J.K. HOSPITAL
Gurgaon (Haryana)



L. N. MEDICAL COLLEGE & J. K. HOSPITAL

(A MCI APPROVED / ISO 9001:2008 CERTIFIED INSTITUTE)



Patient Name	Mrs. Pratibha virendra pandey	Age/Sex	27 Years / FEMALE
Patient ID	1703249223	Visit NO	01
Referred by	DR. POOJA PATIL	Visit Date	17/07/2025
LMP Date	01/03/2025	LMP EDD	06/12/2025

SECOND TRIMESTER SCAN

Present Pregnancy: Single live Intrauterine gestation

- Conception- SPONTANEOUS
- Maternal blood group-B+VE
- NT-NB SCAN, FIRST TRIMESTER BIOCHEMICAL SCREENING NOT DONE.

Obstetric History: G1

Chronic Disease:

- Chronic Hypertension-NO
- Diabetes Mellitus-NO

Family History

- Consanguinity-NO
- Significant Family history-NO

Ultrasound

- Operator - DrSonamVerma , MD RADIO-DIAGNOSIS , Fellowship in Fetal Medicine FMF ID- 277360
- US system - Voluson S10 Expert 22

Transabdominal

Real time B-mode/color/3D ultrasonography of gravid uterus done.
Technically imaging- Good.

Gestational Age:

	Gestation age	EDD
BY LMP	19 weeks 5 days	06/12/2025
BY USG	20 weeks 0 days	04/12/2025

Fetal Survey:


Presentation:	Variable
Placenta :	Anterior (Far Away From The Internal-Os)
Liquor :	Adequate
Umbilical cord:	Two arteries and one vein
Fetal activity:	Fetal activity present
Fetal heart rate:	151,bpm Regular



एल.एन. मेडिकल कॉलेज एवं जे. के. हास्पिटल

(An ISO 9001 : 2008 Certified Institute)

J. K. SUPERSPECIALITY



Name : Pratibha Virendra Pandey

UHID : _____ IPD No. : _____

Age/Sex : 27 Date : 17-7-25

Department : Dr. Sonam Verma

Date of Admission : _____ Date of Discharge : _____

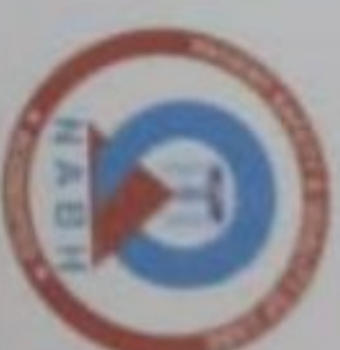Address : _____

वेब साईट : www.Lnctu.ac.in ☎ : 77709 77702
Email : ikhospital@Lnctu.ac.in



L.N. MEDICAL COLLEGE & J.K. HOSPITAL

(A MCI APPROVED / ISO 9001:2008 CERTIFIED INSTITUTE)



NABH ACCREDITED HOSPITAL

ANATOMICAL Fetal SURVEY

HEAD

Normal Skull Shape

Midline falx seen.

Both lateral ventricles appear normal measured 6.8 mm in width.

Posterior fossa structures appeared normal

No identified intracranial lesion seen.

SPINE

Vertebrae and spinal canal appear normal.

No obvious sign of spina bifida or kyphoscoliosis.

FACE&NECK

Both Orbits, nose and mouth appeared normal.

Mandible appears normal.

No evidence of skin oedema or cystic hygroma.

THORAX

Both lung seen.

No evidence of pleural or pericardial effusion.

No evidence of SOL in the thorax.

Heart

Normal cardiac situs.

Normal 4 - chamber view.

Normal 3 - vessels view & 3 - vessels trachea view .

ABDOMEN

Abdominal situs appeared normal.

Stomach bubble & Gall bladder seen.

Normal bowel pattern appropriate for the gestation seen.

No evidence of ascites. Abdominal wall intact.

KUB

Right and Left kidneys, Urinary Bladder appear normal

(AP Dimension of RENAL PELVIS, RT - 1.2 mm & LT - 1.0 mm, within normal limit for this GA.)

Extremities

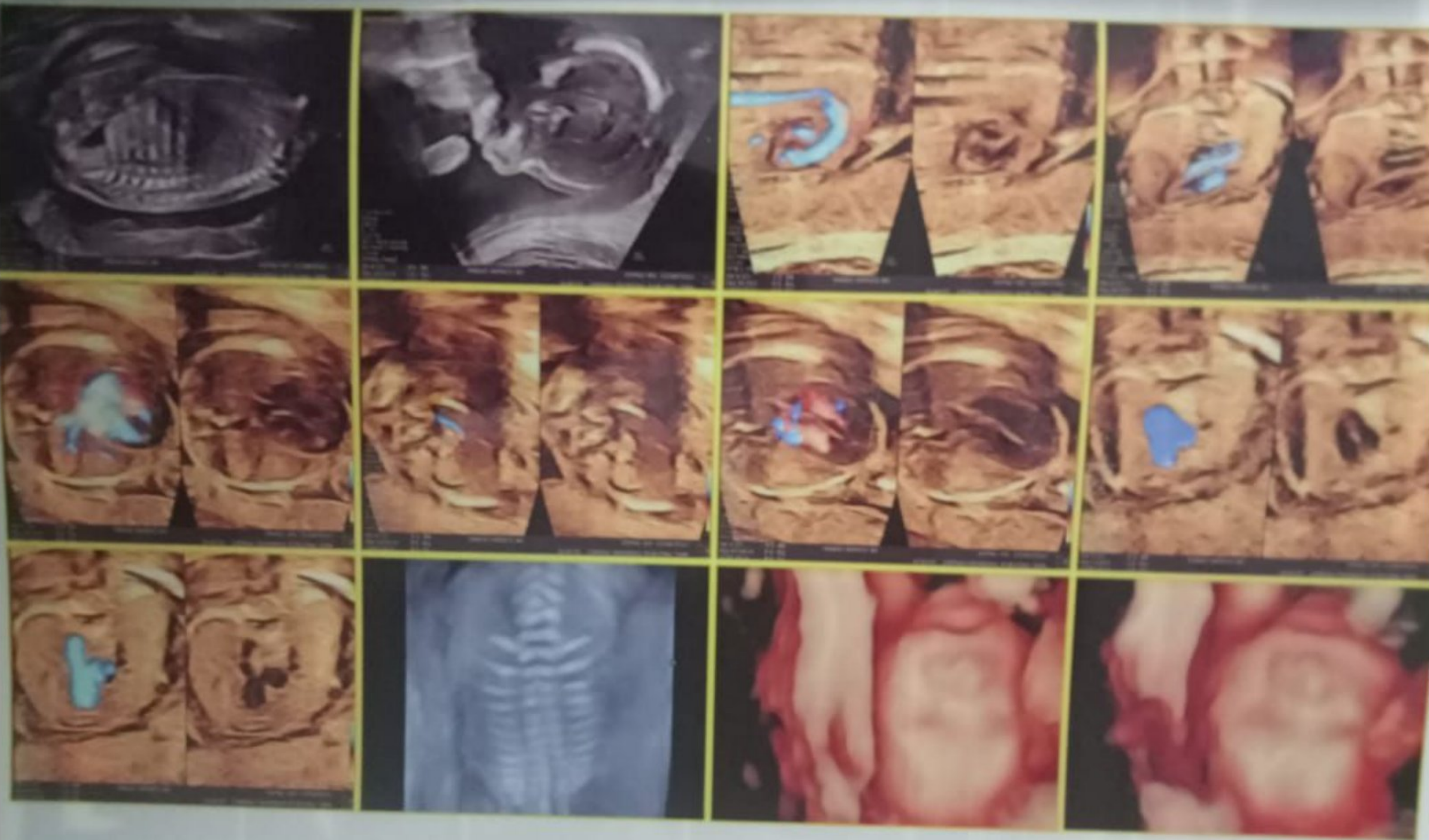All fetal long bones visualized and appear normal for the period of gestation.

Both Hands & feet appeared normal.

Maternal & Fetal Doppler:

Right uterine	Left uterine	Mean	Ductus Venosus
PI:0.89	PI:1.01	PI:0.95	0.96
15.4% + + + + +	31.8% + + + + +	25% + + + + +	

Cervical Assesement : measured 37.2 mm in length with closed os & canal(ON TAS)



Name : MRS. PRATIBHA VIRENDRA PANDEY

L.N. MEDICAL COLLEGE & JK HOSPITAL

17 Jul 2025

Page
(M.P.)
49000