



# ASHIRWAD DIAGNOSTIC CENTRE

SONOGRAPHY • 3D - 4D • COLOUR DOPPLER • 2 D - ECHO • DIGITAL X- RAY

Kohinoor Majestic, 1st Floor, Above Suman Super Market,  
Behind Kundan Hyundai Showroom, Near Thermax Chowk, Chinchwad, Pune 411 019.

Ph. No.: 7722093930 / 9960406686

Timings : Mon to Sat - 9 am to 8:30 pm.

R. HARSHAD ADIK MD-Radio(Mum)

DR. ASHISH ADSULE MD-Radio(Mum), FRCR (UK)

DATE : 09 AUG 2025  
NAME : MRS. KOLHAPURE NAMRATA  
REF. BY : DR. CHAUDHARI SHUBHANGI

## OBSTETRIC USG - ANOMALY SCAN

Uterus is gravid. A single live intrauterine fetus is seen in changing lie.  
Fetal movements and cardiac activity appear normal. FHR is 145 bts/min.  
Liquor appears adequate for the gestational age.

Int.os is closed. Cervical length is around 34 mms.  
Placenta is fundo-posterior. There is no placenta previa.

Right uterine artery PI is 1.01. Left uterine artery PI is 0.77. Mean uterine artery PI is within normal limits for gestational age.

## GROWTH PARAMETERS:

LMP: 26/03/2025

EDD by LMP: 31/12/2025

Period amenorrhea: 19 weeks, 3 days.

BPD: 42 mm HC: 162 mm AC: 142 mm FL: 30 mm HL: 29 mm

Estimated gestational age by USG: Around 19 weeks, 1 day.

Estimated foetal body weight- 290 +/- 42 Gms.

## ANATOMICAL SURVEY:

No obvious fetal malformation is seen in present examination.

## CNS:

The neuroparenchyma appears normal without obvious focal lesion.

There is no shift of midline structures.

The ventricular system appears normal.

Cisterna magna appears normal.

The fetal spine appears normal without obvious neural tube defect.

## Head and neck:

The orbits, nose and mouth appear normal in coronal and profile views.

No obvious soft tissue mass is seen in the neck.

Page 1

are that during the examination, I have neither detected nor disclosed the sex of the foetus to any body in any manner.  
(anomalies can be detected on sonography depending upon various factor like gestational age, fetal position, amount of liquor,  
nal abdominal wall thickness, patient co-operation etc.)

are that by undergoing ultrasonography / image scanning etc. I do not want to know the sex of my foetus.  
करण्यात येणारी सोनोग्राफी ही गर्भलिंग निदानासाठी नाही याची मला जाणीव आहे. यासाठी मी स्वेच्छेने संमती देत आहे.

ture / Thumb impression of pregnant women

Reception Number: 7709029938



# ASHIRWAD DIAGNOSTIC CENTRE

SONOGRAPHY • 3D - 4D • COLOUR DOPPLER • 2 D - ECHO • DIGITAL X- RAY

Kohinoor Majestic, 1st Floor, Above Suman Super Market,  
Behind Kundan Hyundai Showroom, Near Thermax Chowk, Chinchwad, Pune 411 019.

Ph. No.: 7722093930 / 9960406686

Timings : Mon to Sat - 9 am to 8:30 pm.

R. HARSHAD ADIK MD-Radio(Mum)

DR. ASHISH ADSULE MD-Radio(Mum), FRCP (UK)

DATE : 09 AUG 2025

NAME : MRS. KOLHAPURE NAMRATA

REF. BY : DR. CHAUDHARI SHUBHANGI

## Thorax:

Both lungs appear normal without obvious focal lesion.

Normal situs is detected. The heart occupies 1/3<sup>rd</sup> of chest cavity.

The four chambers of heart, interventricular septum, right and left ventricular outflow tracts appear normal. No large VSD is seen. There is no pericardial or pleural effusion.

## Abdomen:

The stomach bubble appears normal.

No abnormal dilatation of bowel loops is seen.

Fetal kidneys and urinary bladder appear normal.

Domes of diaphragm appear normal.

The ventral abdominal and thoracic wall appears intact. No hernia is seen.

## Limbs:

Visualized long bones of all limbs appear normal. There is no evidence of club foot.

## Umbilical cord:

The umbilical cord shows 3 vessels.

## CONCLUSION:

- Single live intrauterine foetus of approximate gestational age 19 weeks, 1 day in changing lie.
- No obvious structural anomaly is detected in present study.

Many thanks for the reference.

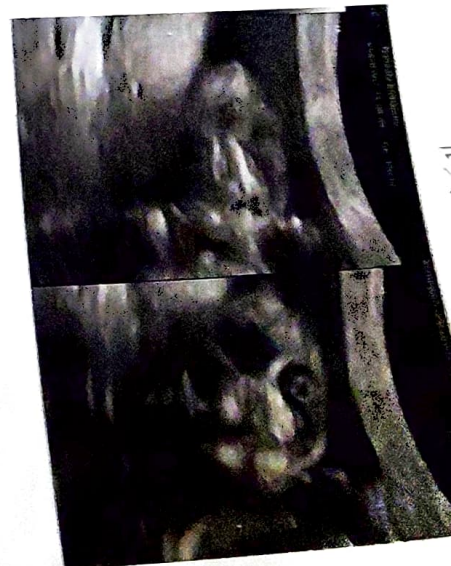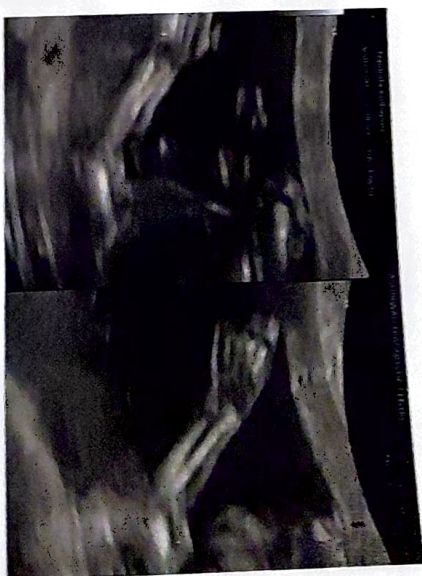
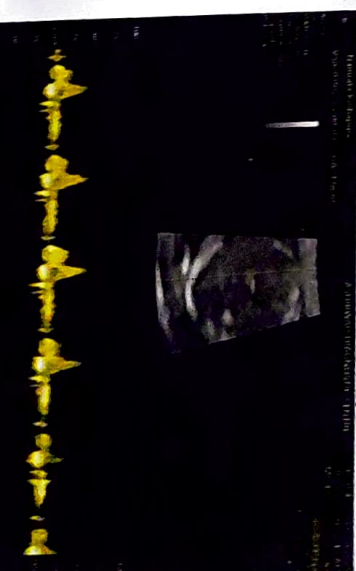
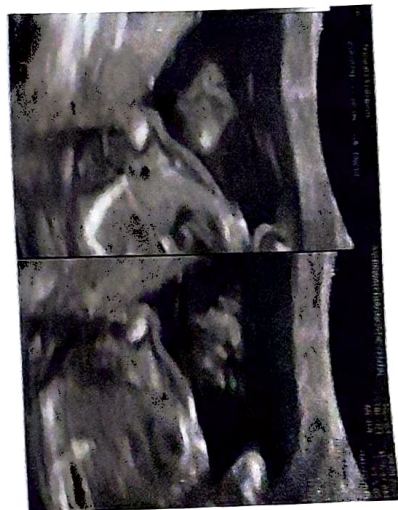
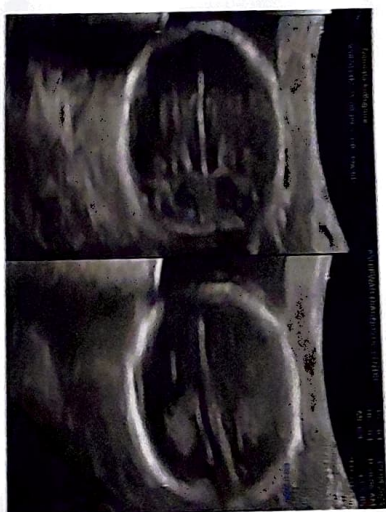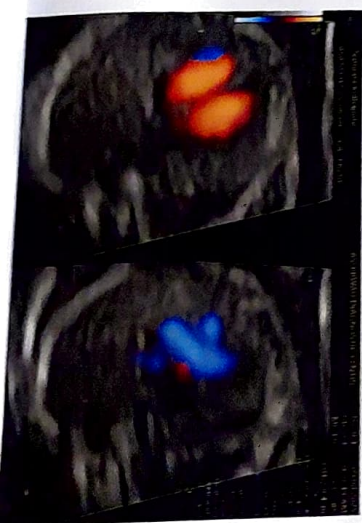
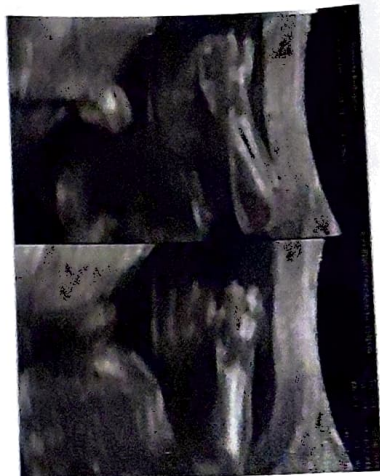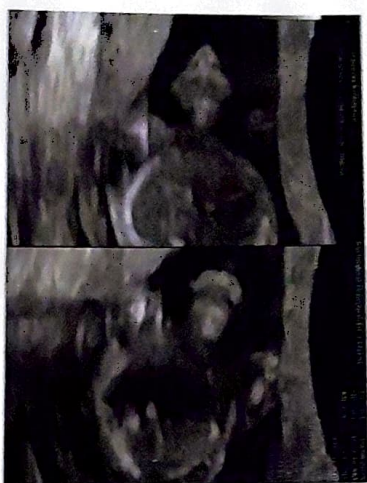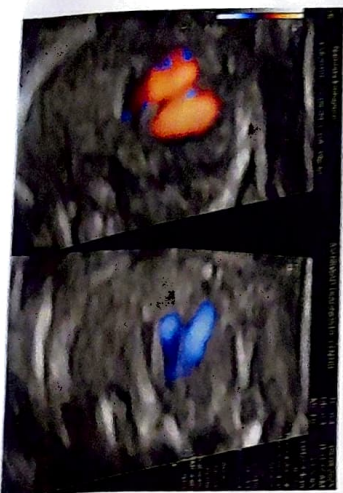
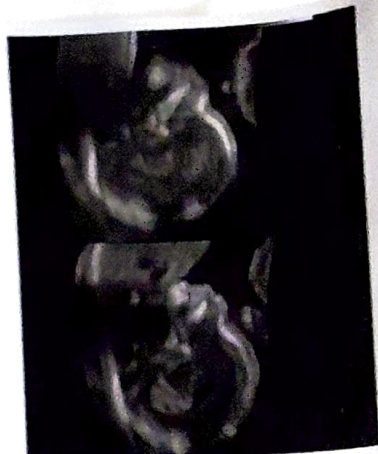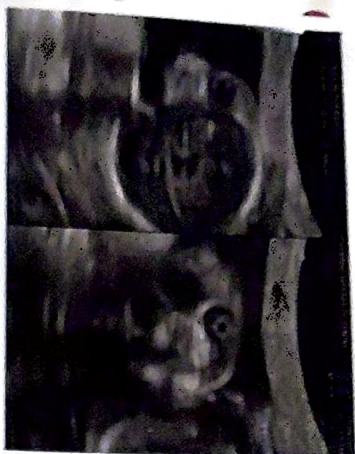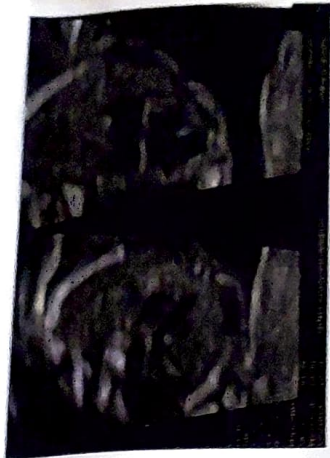Dr. Harshad Adik (MD Radio-Diagnosis)

are that during the examination, I have neither detected nor disclosed the sex of the foetus to any body in any manner.  
(anomalies can be detected on sonography depending upon various factor like gestational age, fetal position, amount of liquor, fetal abdominal wall thickness, patient co-operation etc.)

are that by undergoing ultrasonography / image scanning etc. I do not want to know the sex of my foetus.  
करण्यात येणारी सोनोग्राफी ही गर्भासिंग निदानासाठी नाही याची मला जाणीव आहे. यासाठी मी स्वैच्छेने समती देत आहे.

ture / Thumb impression of pregnant women





पल्या प  
त इतर  
सोज अ  
प्लाही  
वास त  
शु लो  
'रे' त



