



# **Garbhankur Fetal Medicine Centre**

A dedicated care for the Unborn  
**ULTRASOUND | FETAL PROCEDURES | GENETICS**  
Centre of Expertise for Advanced Fetal Care

**Dr. Prashant Asegaonkar**

M.B.B.S., M.S. (OBGY), F.F.M

Consultant Feto-Maternal Medicine Specialist

Fellow & Ex-Consultant in Feto-Maternal Medicine (CIMAR, Kerala)

FMF-UK Certified Sonographer (FMF ID -158741)

MMC REG NO: 2009/12/3764

Mrs. MUSKAN SAYYAD / E83192-25-09-12-1 / 12/09/2025 / Visit No 1

## **EFW (grams)**

BPD, HC, AC, FL 272 (49%)

TCD : 18.6 mm

## **Aneuploidy Markers**

Nasal Bone : Unossified Nasal Bone

Nuchal Fold : 3.1 mm - Nuchal fold thickness appeared normal for the gestational age

## **Fetal Anatomy**

### **Head**

Midline falx seen. Cavum Septum Pellucidum Visualised.

Right lateral Cerebral Ventricle measured 6.5 mm. Left Lateral Cerebral Ventricle measured 6.1 mm.

Both lateral ventricles appeared normal. Posterior fossa appeared normal. No identifiable intracranial lesion seen.

### **Neck**

Fetal neck appeared normal.

### **Spine**

Entire spine visualised in longitudinal and transverse axis. Vertebrae and spinal canal appeared normal

### **Face**

Fetal face seen in the coronal and profile views.

Facial Profile, Both orbits, Palate and nose & mouth appeared normal.

### **Thorax**

Both lungs seen. No evidence of pleural or pericardial effusion. No evidence of SOL in the thorax.

### **Heart**

Heart appears in the mid position. Normal cardiac situs.

Four chamber view normal.

Outflow tracts appeared normal. Three Vessel Tracheal View appeared normal.

### **Abdomen**

Abdominal situs is normal. Abdominal wall intact.

Cord insertion appeared normal.

Stomach and bowel appeared normal. No evidence of ascites.

### **KUB**

Right renal pelvis measured 1.3 mm

Left renal pelvis measured 1.2 mm

Right and Left kidneys appeared normal. Bladder appeared normal

### **Extremities**

All fetal long bones visualized and appear normal for the period of gestation.

Both feet appeared normal. Open hand documented.

Page #2 - 12/09/25

Monday To Saturday Timing - 9:30 am to 7:30 pm For Appointment Call on 7012826880

Address.: Garbhankur Fetal Medicine Centre, Plot No. 49, Jai Vishwabharati Colony,

Chetak Ghoda to Roplekar Square Road, Opposite Sapna Super Market, Chhatrapati Sambhaji Nagar (Aurangabad).

Phone No.: 9890727543 Email Id.: garbhankurfetalmedicine@gmail.com





## ARBHANKUR FETAL MEDICINE CENTRE

A dedicated care for the Unborn

ULTRASOUND | FETAL PROCEDURES | GENETICS

Centre of Expertise for Advanced Fetal Care

Dr. Prashant Asegaonkar

M.B.B.S., M.S. (OBGY), F.F.M

Consultant Feto-Maternal Medicine Specialist

Fellow & Ex-Consultant in Feto-Maternal Medicine (CIMAR, Kerala)

FMF-UK Certified Sonographer (FMF ID -158741)

MMC REG NO: 2009/12/3764

Patient name	Mrs. MUSKAN SAYYAD	Age/Sex	23 Years / Female
Patient ID	E83192-25-09-12-1	Visit no	1
Referred by	Dr. ARSHIYA SULTANA	Visit date	12/09/2025
LMP date	23/04/2025, LMP EDD: 28/01/2026[20W 2D]   C-EDD: 06/02/2026[19W]		

### OB - 2/3 Trimester Scan Report

Real time B-mode ultrasonography of gravid uterus done.

Route: Transabdominal

Single intrauterine gestation

#### Maternal

Cervix measured 3.40 cm in length.

Internal OS appears closed

Right Uterine	1.17	—●— (52%)
Left Uterine	0.68	—●— (3%)
Mean PI	0.925	—●— (23%)

#### Fetus

##### Survey

Presentation - Changing Lie

Placenta - Posterior

Liquor - Adequate

Single deepest pocket = 3.5










Umbilical cord - Two arteries and one vein

Fetal activity present

Cardiac activity present

Fetal heart rate - 156 bpm

#### Biometry (mm)

Biometry (mm)			Long bones	Right (mm)
BPD	44.3, 18W 6D	 (41%)	Tibia	26.3, 18W 6D  (41%)
HC	161.2, 19W	 (47%)	Fibula	26.3, 18W 6D  (41%)
AC	139.1, 19W	 (50%)	Humerus	27.9, 18W 5D  (36%)
FL	28.6, 18W 4D	 (22%)	Radius	23.3, 18W 5D  (29%)
			Ulna	25.8, 18W 1D  (22%)

**Monday To Saturday Timing - 9:30 am to 7:30 pm For Appointment Call on 7012826880**

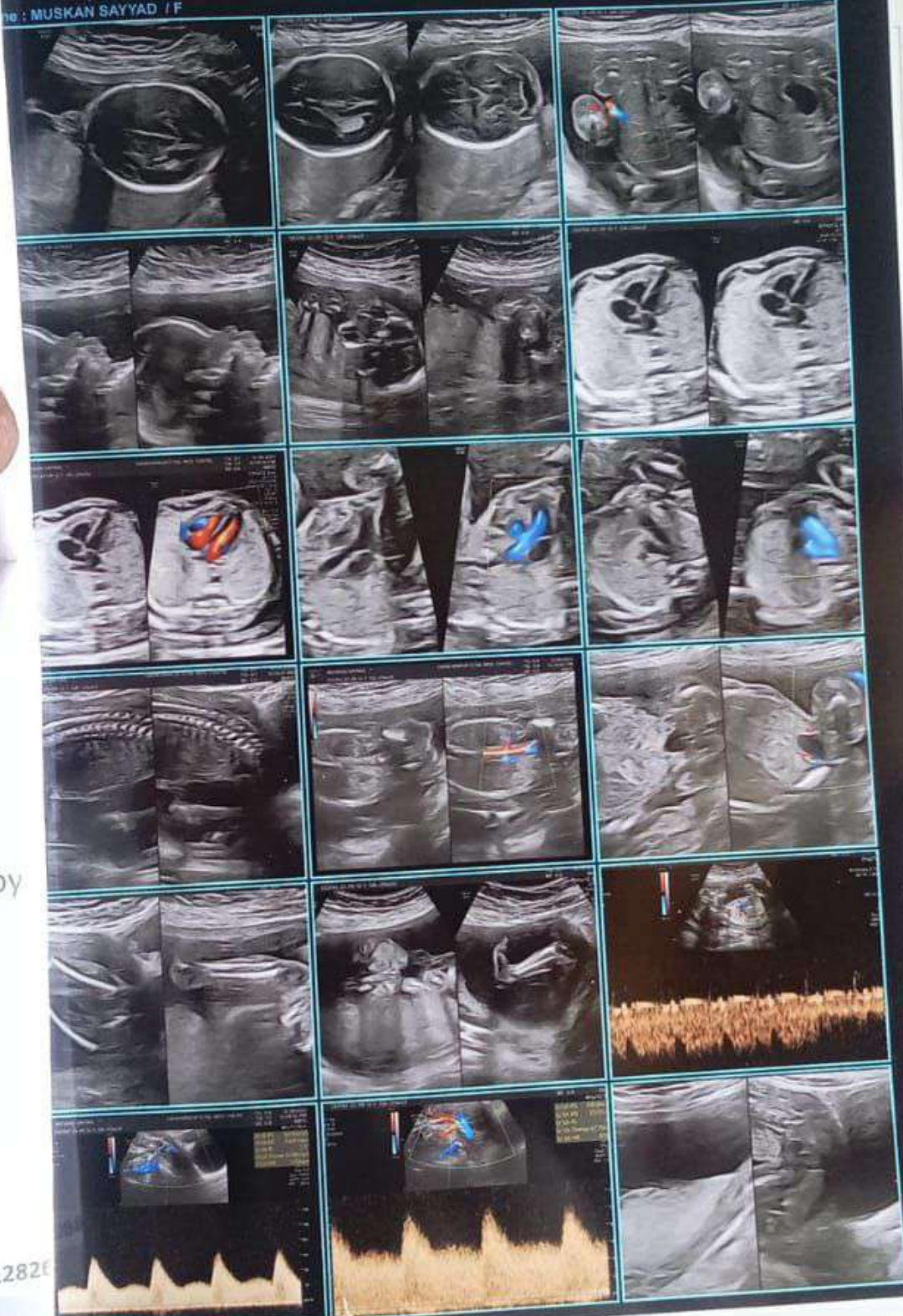Address.: Garbhankur Fetal Medicine Centre, Plot No. 49, Jai Vishwabharati Colony,  
Chetak Ghoda to Roplekar Square Road, Opposite Sapna Super Market, Chhatrapati Sambhaji Nagar (Aurangabad).  
Phone No.: 9890727543 Email Id.: garbhankurfetalmedicine@gmail.com



# GARBHANKUR FETAL MEDICINE CENTRE

12 Sep 2025

ne : MUSKAN SARYAD / F



ening

wins by

( )

on 7012826

lony,  
Nagar (Aurangal







## Garbhankur FETAL MEDICINE CENTRE

A dedicated care for the Unborn

ULTRASOUND | FETAL PROCEDURES | GENETICS

Centre of Expertise for Advanced Fetal Care

Dr. Prashant Asegaonkar

M.B.B.S., M.S. (OBGY), F.F.M

Consultant Feto-Maternal Medicine Specialist

Fellow & Ex-Consultant in Feto-Maternal Medicine (CIMAR, Kerala)

FMF-UK Certified Sonographer (FMF ID -158741)

MMC REG NO: 2009/12/3764

Mrs. MUSKAN SAYYAD / E83192-25-09-12-1 / 12/09/2025 / Visit No 1

### Impression

Single Live Intrauterine gestation corresponding to a gestational age of 19 Weeks

Gestational age assigned as per biometry ( HC )

Menstrual age 20 Weeks 2 Days

Corrected EDD 06-02-2026

**UNOSSIFIED NASAL BONE.**

NO OTHER OBVIOUS MAJOR ULTRASONOGRAPHICALLY DETECTED STRUCTURAL ABNORMALITY IN THE VISUALISED FETAL ANATOMY IN THE PRESENT SCAN.

FOR FURTHER FETAL PROGNOSTICATION, A FETAL INVASIVE DIAGNOSTIC TESTING (AMNIOCENTESIS) IS SUGGESTED TO RULE OUT ANEUPLOIDIES (TRISOMY 21 IN PARTICULAR) & OTHER FETAL CNVS CONCLUSIVELY

### Comments:

- At present scan there is Unossified Nasal bone.
- Second trimester Unossified Nasal bone is a soft tissue marker of Trisomy 21 with a positive likelihood ratio of 6.58.
- Prior aneuploidy screening is not available.
- Fetal Invasive diagnostic testing (Amniocentesis) is recommended in order to rule out aneuploidies (Trisomy 21 in Particular) & Other Fetal CNVs conclusively.
- Monogenic disorders will not be ruled out on Microarray analysis.
- Prenatal USG alone cannot rule out Chromosomal/Gentic disorders in Fetus.
- Patient and Husband counseled.

I DR.PRASHANT ASEGAONKAR HEREBY DECLARE THAT I HAVE NEITHER DETECTED NOR DISCLOSED THE SEX OF THE FETUS TO ANYBODY IN ANY MANNER.

Dr. PRASHANT ASEGAONKAR  
CONSULTANT IN FETAL MEDICINE



### Disclaimer

All anomalies may not be ruled out on ultrasound due to limitations such as- amount of liquor, poor sonographic penetration due to maternal habitus (obesity), previous scar, very early/very advanced gestational age, unfavourable fetal position, late appearance of few evolving anomalies and structures which are not part of routine imaging protocol.

Absence of anomaly on prenatal sonography does not necessarily rule out the possibility of having one postnatally.

Structural normalcy of the fetus is not synonymous with genetic normalcy.

This opinion is based upon the imaging findings at the time of scan and management decisions based on this report must consider the overall clinical setting/scenario and other clinically relevant test results for the patient.

Ultrasound findings are bound to change as the fetus develops.

Page #3 - 12/09/25 01:14 PM

Monday To Saturday Timing - 9:30 am to 7:30 pm For Appointment Call on 7012826880

Address.: Garbhankur Fetal Medicine Centre, Plot No. 49, Jai Vishwabharati Colony,  
Chetak Ghoda to Roplekar Square Road, Opposite Sapna Super Market, Chhatrapati Sambhaji Nagar (Aurangabad).  
Phone No.: 9890727543 Email Id.: garbhankurfetalmedicine@gmail.com





B.H.M.S., A.C.L.S., B.L.S. (Mumbai)  
(Regd No.: 33396)  
+91 7020750679

Time : Morning 10.00 to 2.00 p.m., Evening 6.00 p.m. to 10.00 p.m.

Add.: Beri Bagh, Harsool, Aurangabad. (M.S.)

Rx

Date : 12/9/25

Name : Muskan Arbaz

B.P.:

mmHg

Pulse :

/Min

Sayed

Date of Birth: 7/05/2003.

Age:- 24 yrs. H:- 5 ft. Wt: 57.81 kg

LMP:- 23 April

Investigation Triple Marker

**रियान मेडिकल अँड जनरल स्टोअर्स**

अमर ज्योती डी.एड. कॉलेज जवळ, भगतसिंगनगर रोड, हर्सुल, औरंगाबाद.

मो.: 7020000534.