

PT. NAME	MRS. SANGITA PATEL	AGE	22 /FEMALE
REF. DOCTOR	DR. BINDHU JOSEPH MADEM	DATE	18/10/2025

**ULTRA SOUND EARLY PREGNANCY SCAN(NT-NB SCAN)**

LMP – 01/07/2025      GA (LMP) -15w04d      GA(USG)-12w05d      EDD(USG)- 27/04/2026

**Imaging findings**

Gravid uterus with single intrauterine gestation sac is seen. Decidual reaction is adequate.

Fetal pole seen. Fetal placenta appears forming on anterior wall of uterus.

Fetal cardiac activity is visualized. Fetal heart rate measures 163 beats/min.

CRL measures 6.1 cm corresponding to 12 weeks and 04 day. BPD-2.1cm-13w03d.

FL- 0.9 cm- 13w00d.

*Nuchal thickness within normal limit measures 1.2 mm. Nasal bone is visualized measuring within normal limit 2 mm.*

Chorionic lining is smooth & regular. No evidence of choriodecidual separation seen.

Internal os is closed. Endocervical canal appears normal. Cervical length 3.6 cm.

Myometrium is normal. No obvious myoma noted.

No adnexal mass or ectopic seen.

No free fluid seen in POD.

**Doppler study:**

**Uterine arteries:** Both uterine arteries shows low resistant high diastolic flow pattern. Mean PI value 1.4.

**Umbilical artery:** shows low resistant flow with end diastolic velocity above the baseline. The SD ratio measures 3.7.

**Ductus venosus:** Shows continuous forward flow with normal spectral pattern.

Add : Narayan Nagar, ITI Road, Warehouse Ke Samne, Ward No. 17, Narmadapuram - 461001 Ph.: 07574796266

**Impression:** Gravid uterus with single live intrauterine gestation corresponding to 12 weeks and 05 days seen. Advice - Target scan for after 6 weeks. Normal doppler study at present-----  
? Wrong LMP date ? delayed conception.

- Nuchal thickness within normal limit measures 1.2 mm. Nasal bone is visualized measuring within normal limit 2 mm.
- Ductus venosus Shows continuous forward flow with normal spectral pattern.
- Thorax Normal cardiac situs & position. Four chambers view and out flow tract view appear normal. Both lungs were visualized. No evidence of pleural or pericardial effusion. No SOL seen in thorax. No obvious tricuspid regurgitation (TR) seen.

I, Dr. SUMIT KUMAR VERMA declare that while conducting USG on Mrs. Sangita, I have neither declared nor disclosed the sex of her fetus to anybody in any manner



DR SUMIT KUMAR VERMA, MBBS, MD, PDCC

Consultant Radiologist.

REG. NO. MP-6795

Add : Narayan Nagar, ITI Road, Warehouse Ke Samne, Ward No. 17, Narmadapuram - 461001 Ph.: 07574796266



भारत सरकार  
Government of India



Aadhaar no. issued: 01/11/2011



संगीता पटेल  
Sangita Patel  
जन्म तिथि/DOB: 19/07/2003  
महिला/ FEMALE

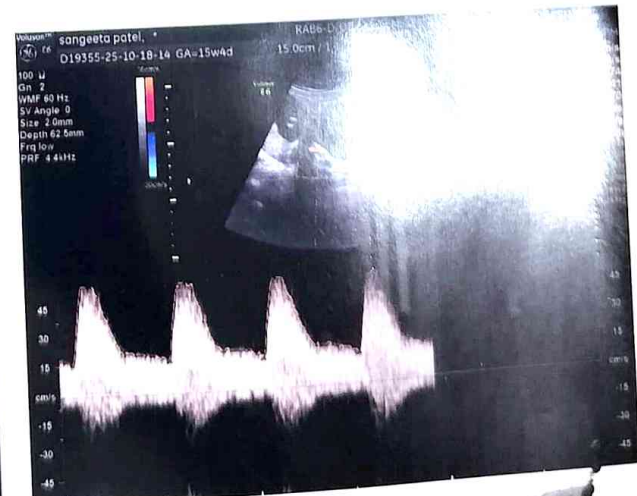
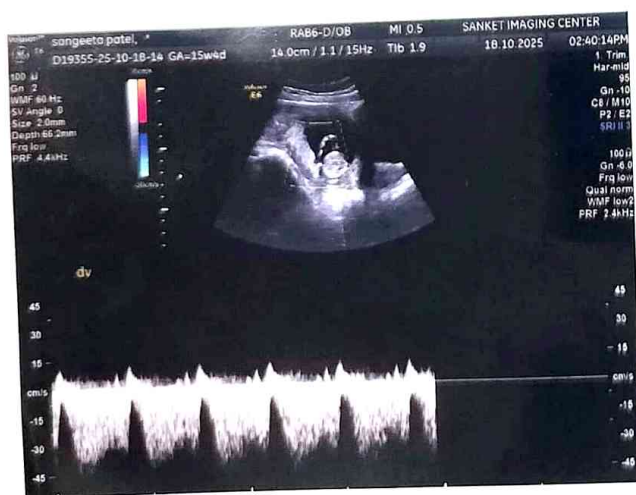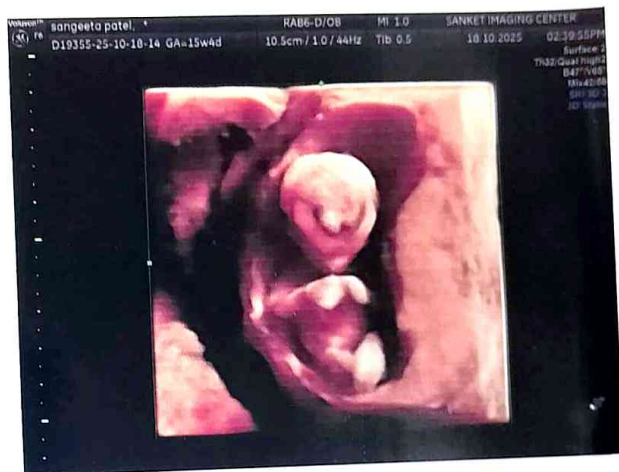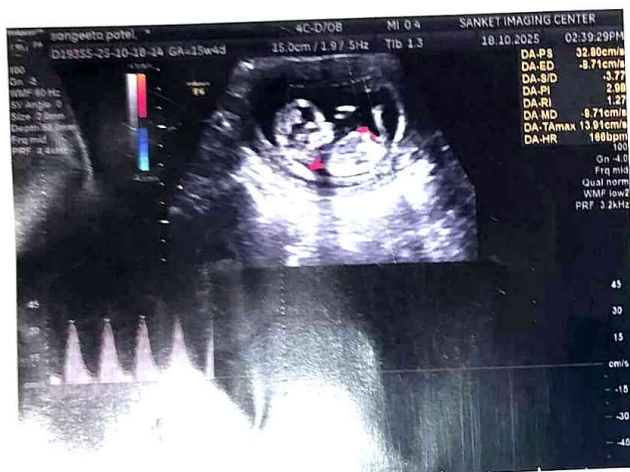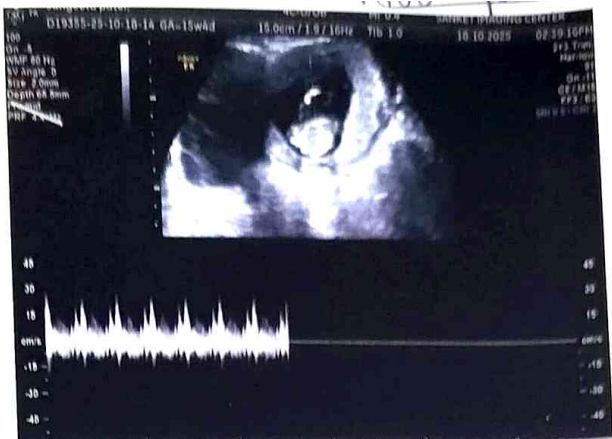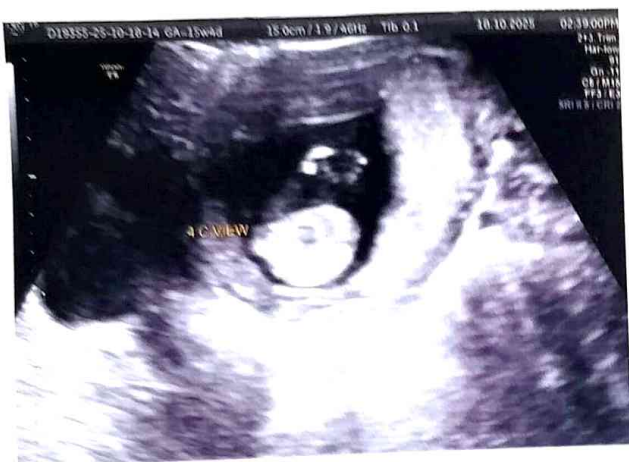आधार पहचान का प्रमाण है, नागरिकता या जन्मतिथि का नहीं।  
इसका उपयोग सत्यापन (ऑनलाइन प्रमाणीकरण, या क्यूआर कोड/  
ऑफ़लाइन एक्सएमएल की स्कैनिंग) के साथ किया जाना चाहिए।  
**Aadhaar is proof of identity, not of citizenship  
or date of birth.** It should be used with verification (online  
authentication, or scanning of QR code / offline XML).

**3485 9602 9986**

**मेरा आधार, मेरी पहचान**



12  
 17  
 26  
 29  
 35  
 32  
 19  
 25  
 1



S  
IM

PT.  
REF.

LMP  
Imag

Grav

Feta

Feta

CRL

FL-C

Nuc

with

Cho

Inte

My

No

No

Do

U

U

S

E