



# समर्पणा

इमेजिंग (सोनोग्राफी) सेंटर, बारशी  
Diagnosis with Care and Excellence

डॉ. मनोज बी. जाधव

MBBS(JJH), MD (RAD), DNB, MNAMS, DICR, EDIR  
FFM (Fellowship in Fetal Medicine), Bangalore  
Ex. Senior Resident Sion Hospital, Mumbai  
Ex. Clinical Associate, Apollo Hospital, Navi Mumbai  
Consultant Radiologist  
Fetomaternal Imaging Consultant  
FMF Certified (11-13 wks Scan)



PATIENT NAME	: MRS. RADHIKA SHIVAJI KARANDE	AGE/SEX	: 23 Years/F
REF. BY	: DR. SADEKAR SHIVAJI, MBBS, MS (OB/GY)	DATE	: 25-Oct-25

## OB-First Trimester Scan Report

LMP: 05-Aug-25	GA (LMP): 11 weeks 4 days	EDD (LMP): 12-May-26
----------------	---------------------------	----------------------

Real time B-mode ultrasonography of gravid uterus done.

**Route:** Transabdominal

### Maternal:

Cervix measured 3.62 cm in length. OS closed.

Right uterine PI : 1.75

Left uterine PI : 1.61

**Mean PI : 1.68 (42 %)**

### Fetus Survey

: Single intrauterine gestation.

Placenta : **Anterior wall.**

Liquor : Normal.

Umbilical cord : Three vessel cord seen.

Fetal activity : Fetal activity present.

Cardiac activity : Cardiac activity present. Fetal heart rate-170 bpm

### Biometry (Headlock)

	Measurement	GA	Percentile	Graph
BPD	1.49 cm	12 weeks 1 days	12.40 %	●
HC	5.51 cm	12 weeks 0 days	12.40 %	●
AC	4.52 cm	11 weeks 2 days	12.40 %	●
FL	0.28 cm	11 weeks 2 days	12.40 %	●
EFW	43 gms	10 weeks 6 days	9.30 %	●

CRL- 3.95 cm. (11 weeks 2 days) IT (Intracranial translucency)-1.8 mm

### Aneuploidy Markers

Nasal Bone : **Not visualized ?Hypoplastic**

Nuchal translucency : 1.2 mm -Normal.

Ductus venosus : No "a" wave reversal.

Tricuspid regurgitation : No tricuspid regurgitation seen.

### Fetal anatomy:

Head : Skull/brain appears normal. Intracranial structures appear normal.

Neck : Neck appears normal.

Spine : Spine appears normal.

Face : PMT and orbits seen.

Thorax : Thorax appears normal.

Heart : Four chamber and outflow tracts appear normal.

Abdomen : Stomach bubble appears normal. Cord insertion seen.

KUB : Bladder appears normal. Kidneys could not be evaluated at present.

Extremities : Both upper limbs and lower limbs seen.

P.T.O

Dr. Manoj B. Jadhav

Reg. No. 2013/07/2596

- Shop No. 5, Near Nikita Hotel, Kurduwadi Road, Barshi - 413401. For Appointment : 74986 48919



# समर्पण

इमेजिंग (सोनोग्राफी) सेंटर, बार्शी

Diagnosis with Care and Excellence

डॉ. मनोज बी. जाधव

MBBS(JJH), MD (RAD), DNB, MNAMS, DICR, EDIR  
FFM (Fellowship in Fetal Medicine), Bangalore  
Ex. Senior Resident Sion Hospital, Mumbai  
Ex. Clinical Associate, Apollo Hospital, Navi Mumbai  
Consultant Radiologist  
Fetomaternal Imaging Consultant  
FMF Certified (11-13 wks Scan)



PATIENT NAME	:	MRS. RADHIKA SHIVAJI KARANDE	AGE/SEX	:	23 Years/F
REF. BY	:	DR. SADEKAR SHIVAJI, MBBS, MS (OB/GY)	DATE	:	25-Oct-25

## IMPRESSION:

- > Single live intrauterine gestation corresponding to gestational age of 11 weeks 2 days.
- > Menstrual age is 11 weeks 4 days.
- > EDD by USG (Biometry-CRL): 14-May-26
- > Assigned EDD (As per LMP): 12-May-26
- > Nasal bone is Not visualized ?Hypoplastic.
- > Nuchal translucency (1.2 mm), tricuspid regurgitation: within normal limits.
- > Endocervical length: 3.62 cm: Normal however it will be best assessed after 14 weeks.
- > Uterine artery screen negative for PET.
- > - No obvious sonological structural abnormalities detected for this gestation.

## SUGGEST:

- 1) Double marker test today.
- 2) TIFFA (level II) scan between 18-20 weeks.

Thanks for the reference,  
With regards.

**Please Note:** All abnormalities and genetic syndromes cannot be ruled out by ultrasound examination. Ultrasound examination has its own limitations. Some abnormalities evolve as the gestation advances. The pickup rate of abnormality depends on gestational age of the fetus, fetal position, tissue penetration of sound waves, and patient's body habitus.

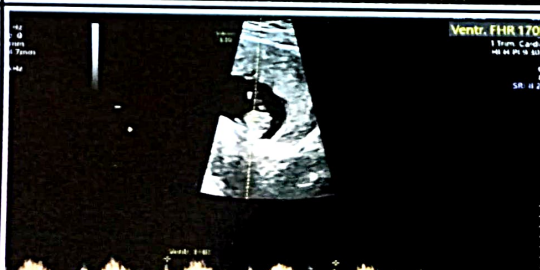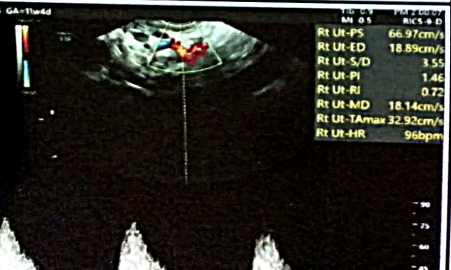
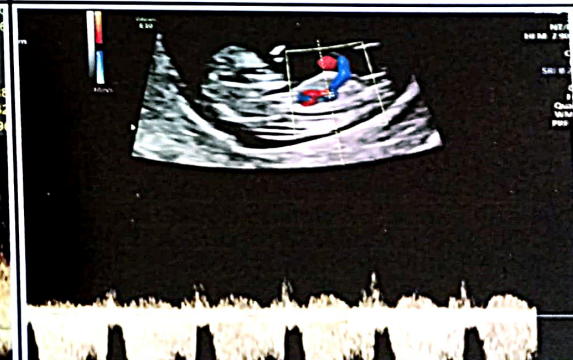
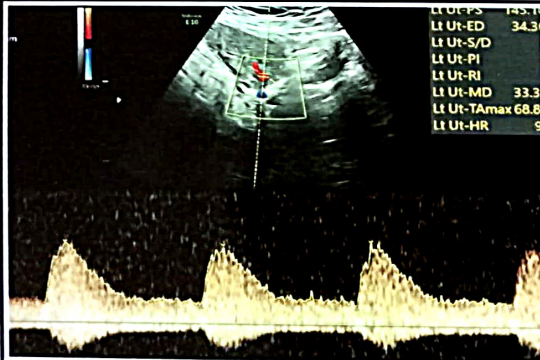
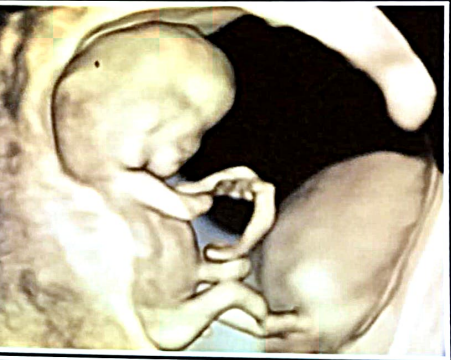
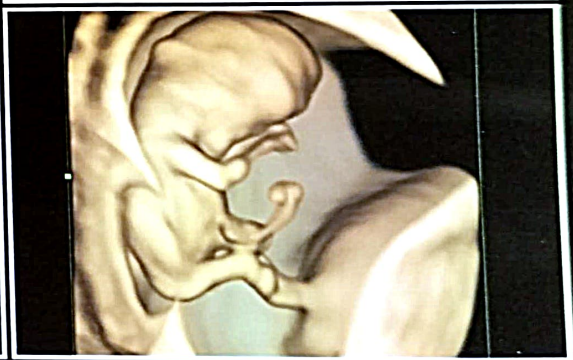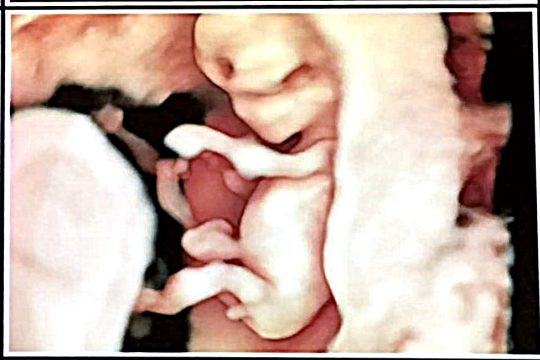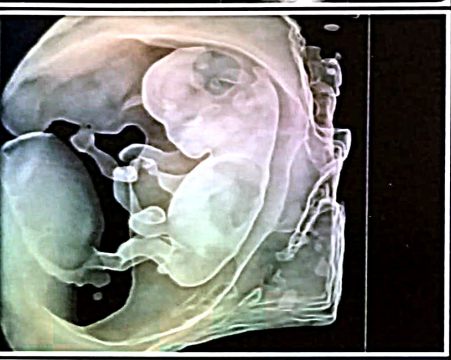
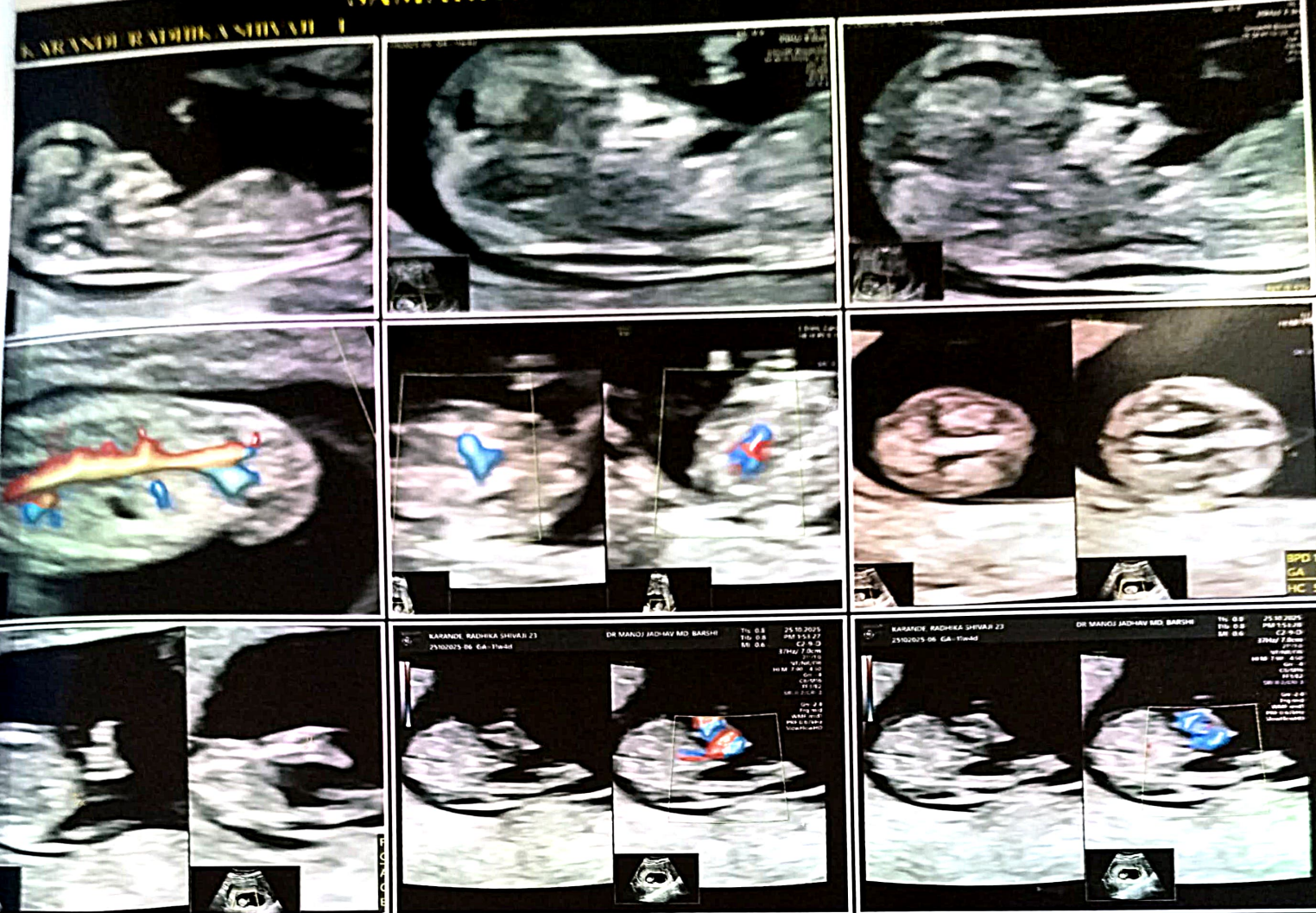**Disclaimer:** I Dr. Manoj B. Jadhav declare that while conducting ultrasonography/image scanning on this patient, have neither detected nor disclosed the sex of her fetus to anybody in any manner.

Best Wishes,  
For Appointments Please Contact: 7498648919.

  
Dr. Manoj B. Jadhav



KARANDE RADHIKA SHIVAJI 23



DR MANOJ JADHAV MD, BARSHI		Date of Exam: 25.10.2025		Page: 1/10	
Name: KARANDE RADHIKA SHIVAJI		DOB: 25.10.2002		Sex: Female	
Preg ID: 25102025-06		Ref Phys: Dr. MANOJ B. JADHAV		Ref: Dr. SAKHAR SHIVAJI	
Indication:		Sonogr:		Gestational Age: 11w4d	
LMP: 05.08.2025	GALLMP: 11w4d	EDD/LMP: 12.05.2026	G: 1	A6	
DOC:	GA/LMP: 11w4d	EDD/LMP: 12.05.2026	P: 1	Ec	
ACR/DOPPLER		Value: 43g	Range: 40g - 46g	Age: 11w4d	GP: 9.3%
3D Measurements		Value	ml	ml	ml
HC (Head Circ)	ml	5.48 cm	5.49	5.48	5.48
AC (Abdom Circ)	ml	5.55 cm	5.51	5.55	5.55
FL (Femur Length)	ml	4.52 cm	4.52	4.52	4.52
FTL (Fetal Thorax Length)	ml	0.28 cm	0.28	0.28	0.28
CTL (Chest Length)	ml	4.49 cm	4.49	4.49	4.49
NT	ml	0.12 cm	0.12	0.12	0.12





M Imp - 05 August 2025

P DOB - 29 Oct - 2004

F Weight - 80 kg

Height - 5 ft.

mob - 8824083036

Bp : 1W/AS