

Nova Polyclinic

Diagnostic & Day Care Center



DR. ABDUL HAKEEM

M.B.B.S., M.D. (Radiodiagnosis)

LTMMC & GH (Sion Hospital, Mumbai)

Consultant Interventional Diagnosis

Radiologist & Sonologist

● 3D/4D SONOGRAPHY ● WHOLE BODY COLOR DOPPLER ● TARGET SCAN ● ECG/2D ECHO ● DIGITAL X-RAY ● FNAC/BIOP.

NAME : MRS. PUSHPA SINGH
REF BY : DR. UMA NIGAM

AGE/SEX : 22YRS / F
DATE : 27/10/2025

USG OBSTETRIC NT /NB SCAN

- This examination shows bulky uterus with early intra uterine pregnancy. There is well defined gestational sac with single embryonic pole.
- Foetal cardiac activity is present and is regular. FHR is 157 BPM.
- Placenta is along the **anterior wall** (grade 0 maturity), away from the internal OS.
- The internal os is closed. The cervical length is **adequate**. (Measures 2.7cm)
- Diencephalon: Normal ✓
- Ductus venosus: Normal (No reversal of flow is seen)
- Tricuspid regurgitation: absent ✓
- Fundic bubble: seen, ✓
- Urinary bladder: Normal ✓
- Both uterine arteries show normal PI. (Right uterine artery PI is 1.38 & left uterine artery PI is 1.47).
- Fetal movement: Present ✓
- Both ovaries and adnexa are normal.
- Fetal parameters are as follows.

NUCHAL THICKNESS	1.3mm
NASAL BONE	seen ms 2.9mm
CRL	6.39cm corresponds to 12 weeks 06 days
EDD (USG)	05/05/2026

IMPRESSION:

- **SINGLE LIVE EARLY INTRAUTERINE GESTATION OF 12 WEEKS 06 DAYS.**
- **NORMAL NT NB SCAN.**

SUGGEST: DUAL MARKER & CLINICAL CORRELATION.

Please note:

* I Dr. ABDUL HAKEEM declare that while conducting ultrasonography scanning on MRS PUSHPA SINGH I've neither detected nor disclosed the sex of fetus to anybody in any manner. The consent forms for the same are filled as per P.N.D.T. act rules.

Thanks for reference.

DR. ABDUL HAKEEM

MBBS, M

CONSULTANT RADIOLOGIST

SION HOSPITAL, MUMBAI

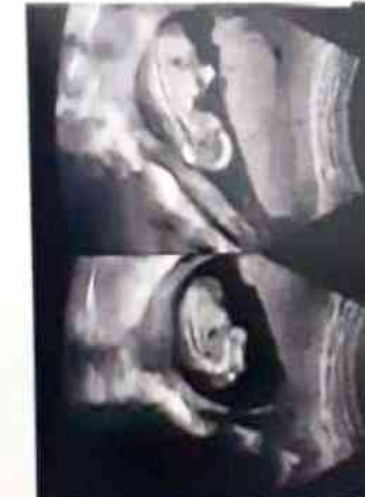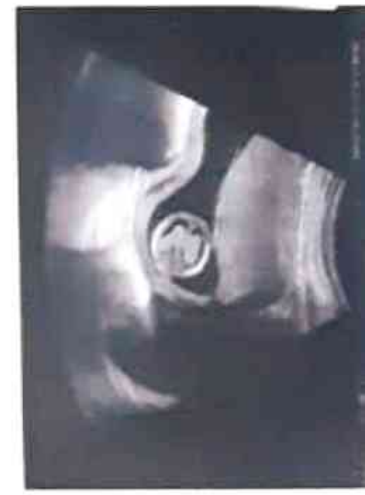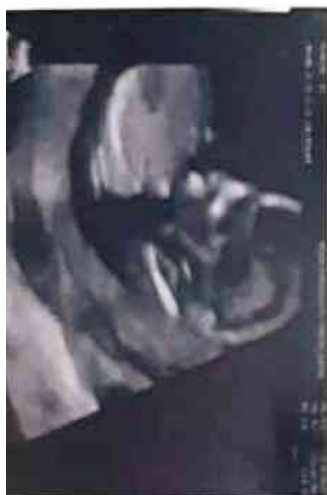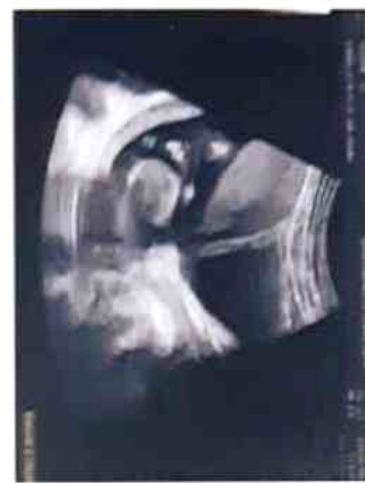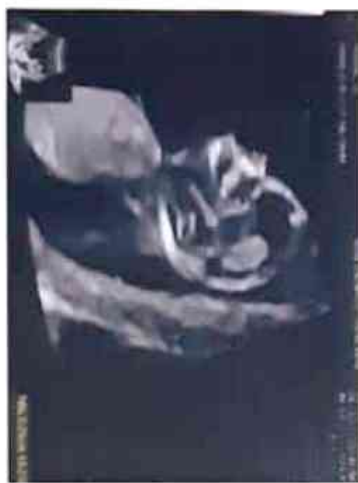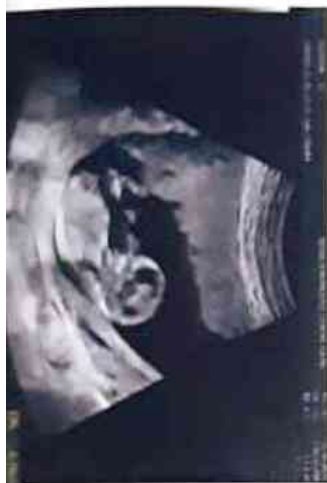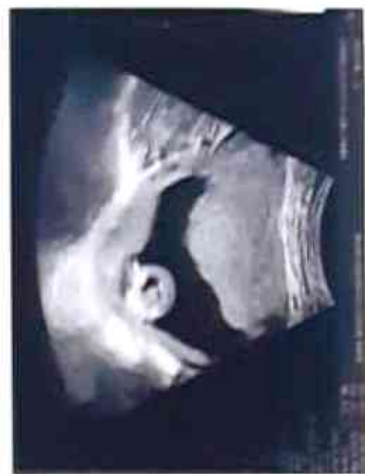
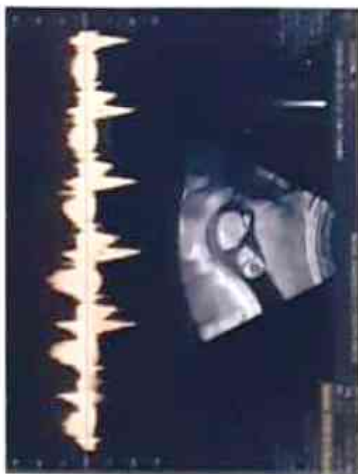Registration no. MP- 403

Investigations have their limitations; solitary radiological tests never confirm final diagnosis and they can only help in diagnosing the disease in correlation with other tests. Kindly interpret accordingly. Patient identity is not verified by Police; hence this report is NOT FOR MEDICOLEGAL PURPOSE. If there is any physical error in the report, the patient should contact the center immediately to have it corrected.

mail : novadiagnosticcenter8@gmail.com ☎ 07622-489467

☎ Mob. : 9004334

बैंक के बगल में, सागर पुल के पास, कटनी (म.प्र.) 483501, Timing : 09AM - 9PM (Sunday 09 AM - 0





भारतीय विशिष्ट पहचान प्राधिकरण

Unique Identification Authority of India



पता:

आत्मजा: रंजीत सिंह, रगौली, पोस्ट रागुवान, रेग्गान, पन्ना,
मध्य प्रदेश - 488448

Address:

D/O: Ranjeet Singh, ragouli, post raiguwan,
Raiguwan, Panna,
Madhya Pradesh - 488448



9357 6784 9871

5107 8819 4255 9629



1947

uidai.gov.in



www.uidai.gov.

भारत सरकार
Government of India



पुष्पा सिंह
Pushpa Singh
जन्म तिथि/DOB: 18/03/2004
महिला/ FEMALE

Issue Date: 02/08/2021

9871

VID 9107 5819 4255 9629

मेरा आधार, मेरी पहचान

Nova Polyclinic

Diagnostic & Day Care Center



DR. ABDUL HAKEEM
M.B.B.S., M.D. (Radiodiagnosis)
LTMMC & GH (Sion Hospital), M
Consultant Interventional Di
Radiologist & Sonologist

• 3D/4D SONOGRAPHY • WHOLE BODY COLOR DOPPLER • TARGET SCAN • ECG/2D ECHO • DIGITAL X-RAY • FNAC

NAME : MRS. PUSHPA SINGH
REF BY : DR. UMA NIGAM

AGE/SEX : 22YR
DATE : 27/10

USG OBSTETRIC NT /NB SCAN

- This examination shows bulky uterus with early intra uterine pregnancy. There is v defined gestational sac with single embryonic pole.
- Foetal cardiac activity is present and is regular. FHR is 157 BPM.
- Placenta is along the **anterior wall** (grade 0 maturity), away from the internal OS.
- The internal os is closed. The cervical length is **adequate**. (Measures 2.7cm)
- Diencephalon: Normal ✓
- Ductus venosus: Normal (No reversal of flow is seen)
- Tricuspid regurgitation: absent ✓
- Fundic bubble: seen, ✓
- Urinary bladder: Normal ✓
- Both uterine arteries show normal PI. (Right uterine artery PI is 1.38 & left uterin artery PI is 1.47).
- Fetal movement: Present ✓
- Both ovaries and adnexa are normal.
- Fetal parameters are as follows.

NUCHAL THICKNESS	1.3mm
NASAL BONE	seen ms 2.9mm
CRL	6.39cm corresponds to 12 weeks 06 days
EDD (USG)	05/05/2026

IMPRESSION:

- **SINGLE LIVE EARLY INTRAUTERINE GESTATION OF 12 WEEKS 0 DAYS.**
- **NORMAL NT NB SCAN.**

SUGGEST: DUAL MARKER & CLINICAL CORRELATION.

Please note:

* I Dr. ABDUL HAKEEM declare that while conducting ultrasonography scanning on MRS PUSHPA SINGH I've neither detected nor disclosed fetus to anybody in any manner. The consent forms for the same are filled as per P.N.D.T. act rules.

Thanks for reference.

DR. ABDUL HAKEEM

CONSULTANT RADIOLOGIST
SION HOSPITAL,
Registration no.

Notes: Investigations have their limitations; solitary radiological tests never confirm final diagnosis and they can only help in diagnosing the disease & symptoms and other tests. Kindly interpret accordingly. Patient identity is not verified by Police; hence this report is NOT FOR MEDICOLEGAL PURPOSE. In case of any typographical error in the report, the patient should contact the center immediately to have it corrected.

Email : novadiagnosticcenter8@gmail.com 07622-489467

Mob. : 90

CICI बैंक के बगल में, सागर पुल के पास, कटनी (म.प्र.) 483501, Timing : 09AM - 9PM (Sunday 09