

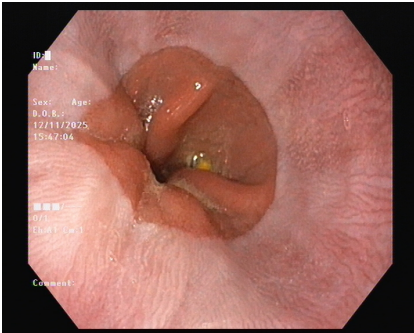
VRRIDDHI GASTRO AND LIVER CLINIC
SHOP NO F-14, F-RESIDENCY, NEAR BRAMHA SUN CITY, KALYANI NAGAR
PUNE - 411014

Phone No: 8380005080/ 020-29911665
Email_ID: VRRIDDHICLINIC@GMAIL.COM

Patient ID: 2025110034
Name: Mr. Jalinder Bhambhure
Age: 46 Y Sex: M
Date: 12-Nov-2025

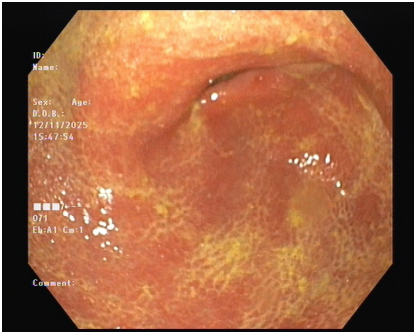
Ref By: Dr. Sudhir Shinde
Study: UPPER GI ENDOSCOPY
Examined By: Dr. Akshay Kale
DrNB GASTRO

UPPER GI ENDOSCOPY REPORT



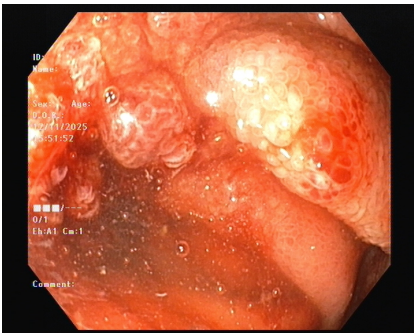
INDICATION- ABDOMINAL PAIN, VOMITTING, CECT ABDOMEN S/O- MASS OF UNCINATE PROCESS INVOLVING DUODENAL WALL

ANASTHESIA- LOCAL XYLOCAINE SPRAY



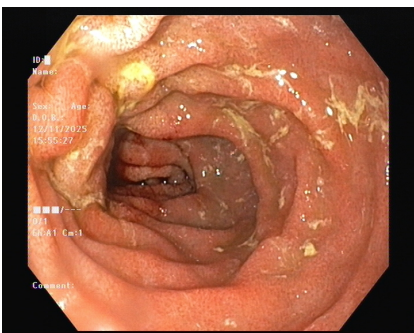
ESOPHAGUS- showed erosions at GE junction suggestive of LA grade B reflux esophagitis. No obvious ulcer or mass was seen.

STOMACH- The entire stomach mucosa was edematous and showed erythema. Lot of food particles were seen in stomach.



DUODENUM- showed tight narrowed third part of duodenum just distal to ampulla. The strictured area was edematous and showed ulceroproliferative growth around it which bleed easily on touch. Multiple biopsies taken for HPE. The scope could not be negotiated beyond the stricture.

**IMPRESSION-DUODENAL STRICTURE ??MALIGNANT
PANGASTRITIS**



ADV- NJ TUBE PLACEMENT, WHOLE BODY PET CT IF OPERABLE THEN SURGERY OR ELSE LUMINAL STENTING

Dr. Akshay Kale

MBBS, MD, DrNB GASTRO

Fellowship in Advanced and Third Space Endoscopy

Fellowship in EUS and ERCP