

वसुधा

3D / 4D सोनोग्राफी व डिजीटल एक्स-रे सेंटर

डॉ. लक्ष्मीकांत दे. कळंबे

MBBS DMRE (Mumbai)
Consultant Radiologist
Reg.No. 2016/10/4386

PATIENT NAME	:	MRS. PRANITA RAVI PURANKAR	AGE/SEX	:	25 YEARS/F
REF. BY	:	DR. SHUBHANGI CHABILE MADAM	DATE	:	27 Dec 2025

IMPRESSION:

➤ Single live intrauterine gestation corresponding to gestational age **12 Weeks 4 Days**.

EDD (As per CRL): 07 Jul 2026.

➤ Normal NT scan.

NIPT / Double marker correlation.


Suggested: Anomaly scan TIFFA (level II) between 18-20 weeks.


Disclaimer:

I Dr. Laxmikant Kalambe, declare that while conducting ultrasonography/image scanning on this patient, have neither detected nor disclosed the sex of her fetus to anybody in any manner.

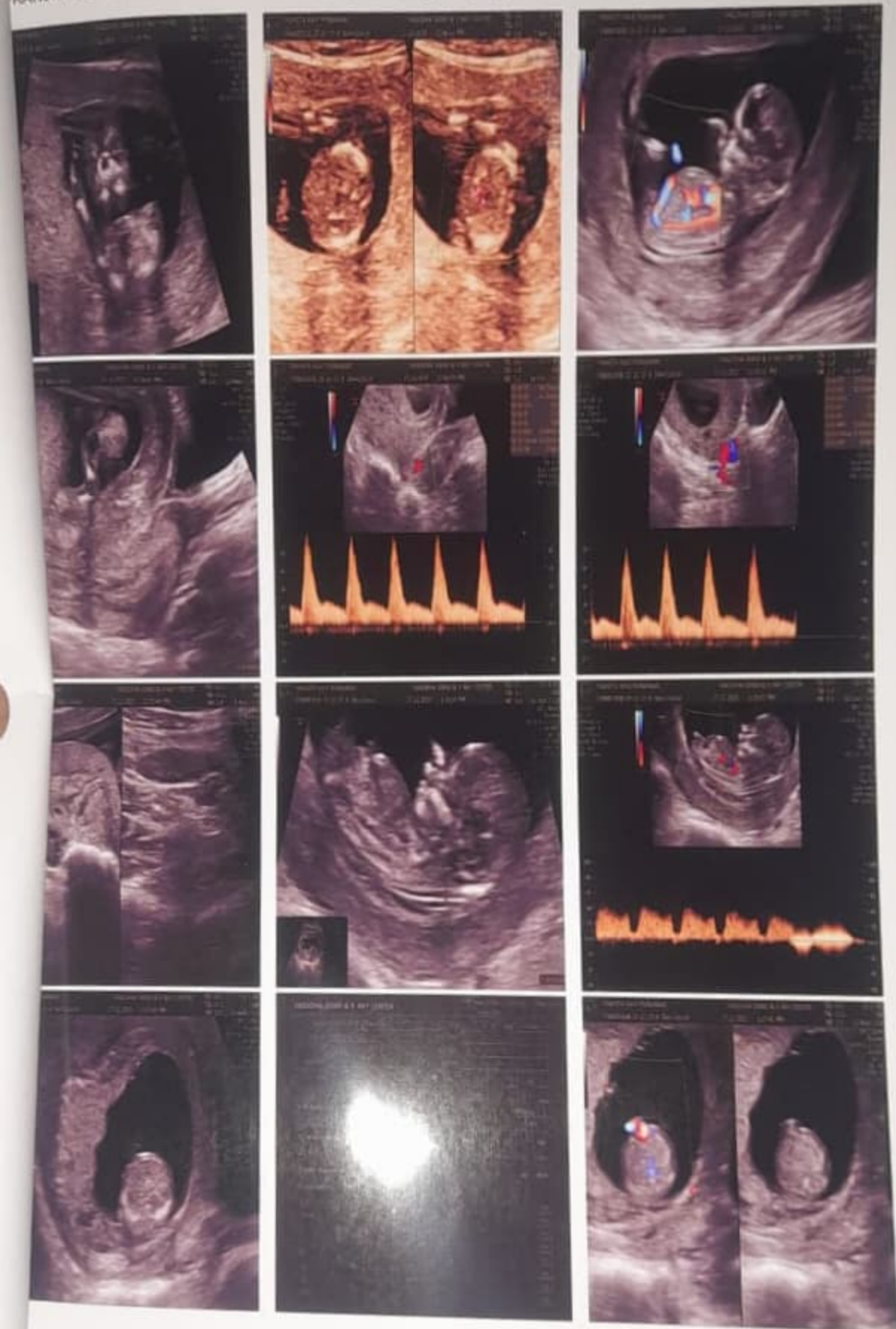Thanks for the reference,
With regards.

गरोदरपणाची नोंदणी नजीकच्या
पा.आ.केंद्र/ग्रामिण रुग्णालय येथे
चरीत करण्याच्या सुचना डॉक्टर
कडून प्राप्त झाल्या.



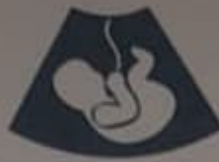
Dr. Laxmikant D. Kalambe
MBBS DMRE.
Reg. No. 2016/10/4386
Consultant Radiologist

- This imaging modality has its own limitations and not 100% accurate. The impression mentioned above are only suggestion of diagnosis and not the final diagnosis by itself. Please correlate with clinical findings & suggested further evaluation if clinically warranted.
- This report cannot be used for medic legal purpose.



रिशिकृपा

सोनोग्राफी अँड डायग्नोस्टिक सेंटर



डॉ. ऋषिकान्त रमेश काटे

M.B.B.S. DMRE (CONSULTING RADIOLOGIST)

Reg.No. 2015/06/3597

FETAL MEDICINE FOUNDATION (UK)

FMF ID- 240686

डॉ. काटे पाटील टॉवर, जिजाऊ चौक, इंदरप्रस्थ हॉटेलच्या बाजूला, मेन रोड, मेहकर ☎ 7499805785

Name: Mrs. PRATIKSHA RAVI PURANKAR
Age: 25 Years
Sex: Female

Ref By: Dr. SHUBHANGI R CHHABILE Mam
Study: OBSTETRICS Visit No-1
Date: 05-Nov-2025

EARLY OBSTETRIC ULTRASOUND EXAMINATION(TVS)

The real time, B mode, Gray scale sonography of gravid uterus was performed trans-Vaginally using a pure wave technology by GE Volusion S-8 BT-18 machine.

Visualisation: Good.Route:- Transvaginal.

LMP: 18/09/2025.

EDD by dates: 25/06/2026.

Indication-To diagnose intra-uterine and/or ectopic pregnancy and confirm viability.Estimation of gestational age (dating).

GESTATIONAL AGE:6 weeks 1 day from Gestational sac EDD by this scan: 30/06/2026.

MATERNAL:

- Internal os is closed. • Cervical length= 3.6 cm.
- No obvious corpus luteal cyst on either side.
- Right Adnexa: appears normal. • Left Adnexa: appears normal.

OBSTETRICS FINDINGS:

- Gravid anteverted uterus shows presence of an intrauterine gestational sac with no foetal pole appreciated.
- Foetal pole is not appreciated.
- Average gestational sac diameter is 1.26 cm = 6 weeks 1 day.
- Yolk sac is seen.

IMPRESSION:

- A single intrauterine gestational sac corresponding to 6 weeks 1 day with no foetal pole appreciated at present follow up after 2 weeks for viability.

SUGGEST:Follow up scan is recommended after 2 weeks for foetal pole and viability.

Photos with declaration form enclosed.

DECLARATION: I Dr. RISHIKANT KATE declare that while conducting ultrasonography/image scanning etc. on this patient, I have neither detected nor disclosed sex of her fetus to anybody in any manner.



Dr. RISHIKANT KATE
M.B.B.S. DMRE (Radiologist)
Reg No-2015/06/3597.
Fetal Medicine Foundation(UK)
FMF ID - 240686

IS नॉटणी कसन घ्यावी
ent is Advised For
S Registration


Toshniwal Diagnostic & Skin Clinic

Sonography / Colour Doppler / X-Ray / Obsteric Scan / 3D / 4D Scan / Skin / Laser / Hair

Dr. Akshay Toshniwal

Consultant Radiologist
(MBBS DMRE) RADIOLOGY

& Anomaly Scan Certified (FMP UK)
Fetal Medicine Foundation (FMP) Certified, London UK



Dr. Komal A. Toshniwal

MBBS, DDV (स्नातकोत्तर व सौंदर्य चिकित्सा)
Consultant Dermatologist (MGM Sambhajinagar)
Aesthetics & Dermatosurgery (Bion, Mumbai)
Fellowship in Lasers & Cosmetology (Mumbai)

Name of patient:	Mrs. Pranita Purankar	Age & sex	25 yr / F
Ref by:	Dr. Pallavi Kad Ma'am	Scan date:	22-11-2025

ANTENATAL ULTRASOUND SCAN (FIRST TRIMESTER): Reason for exam : Foetal viability and dating scan.

LMP : 18/09/2025

Gestational age by LMP : 9 weeks and 2 days.

EDD by LMP : 25/06/2026

EDD by AUG : 10/07/2026

Uterus : gravid

Gestational Sac : single

Foetal pole : seen

Yolk sac : seen

Fetal heart : seen. FHR : 163 bpm

CRL measures 10.47 mm corresponding to 7 weeks 1 days.

Trophoblastic Reaction : good

Adnexa : no mass.

Right ovary: normal.

Left ovary: normal.

Internal os: closed.

-Thin rim of Subchorionic bleed seen around G-sac measuring ~11 x 2.9 mm in size.

IMPRESSION

25 year old lady for early pregnancy scan,

ANTENATAL ULTRASOUND shows:

- Single, intra-uterine live pregnancy corresponding to 7 weeks 1 days of gestation.
- Thin rim of Subchorionic bleed seen around G-sac measuring ~11 x 2.9 mm in size.
- Corrected EDD : 10/07/2026

Recommend NT scan at 12 -13 weeks.

I, Dr. Akshay Toshniwal, declare that while conducting Ultrasonography on Mrs. Pranita Purankar, have neither detected nor disclosed the sex of her foetus to anybody in any manner.

Dr. Akshay Toshniwal

DR. AKSHAY TOSHNIWAL

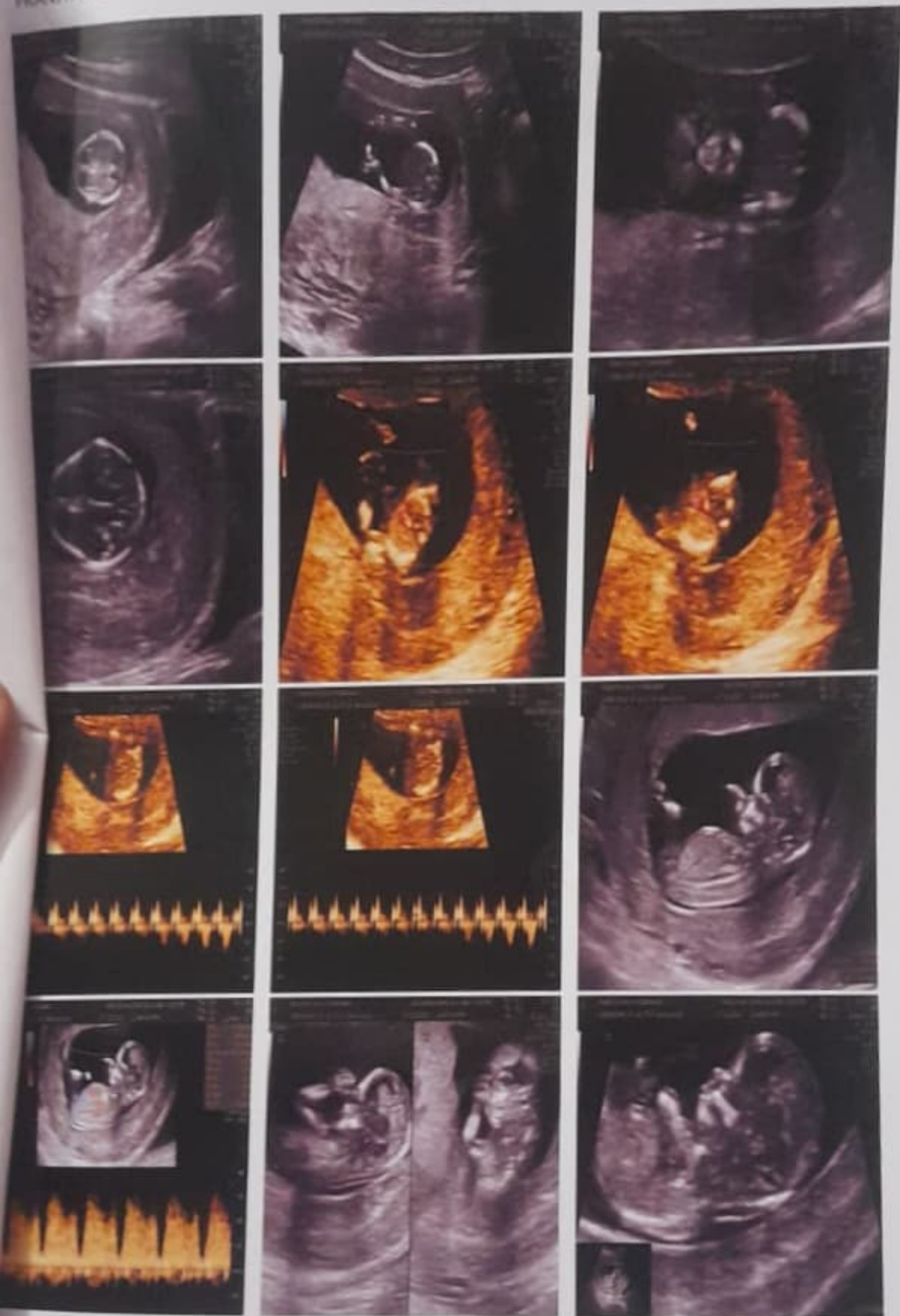Reg No. 2018040796

Fetal Medicine Foundation Certified.

REG. NO. 2018040796

FMP ID-268956

FMP ID-268956





वसुधा

3D / 4D सोनोग्राफी व डिजीटल एक्स-रे सेंटर

डॉ. लक्ष्मीकांत दे. कळंबे

MBBS DMRE (Mumbai)
Consultant Radiologist
Reg.No. 2016/10/4386

PATIENT NAME	: MRS. PRANITA RAVI PURANKAR	AGE/SEX	: 25 YEARS/F
REF. BY	: DR. SHUBHANGI CHABILE MADAM	DATE	: 27 Dec 2025

OB-First Trimester Scan Report with NT Scan

Real time B-mode ultrasonography of gravid uterus done.

EDD (BY PRIVOIES USG):10.07.2026	GA (EDD): 12 WEEKS 1 DAYS
----------------------------------	---------------------------

Route: Transabdominal

Maternal:

Cervical length measures 4.0 cm. Internal os is closed.

Uterine artery:

Right uterine PI : 2.22

Left uterine PI : 2.15

Mean uterine PI : 2.18 – Normal.

Fetus Survey : Single live intrauterine gestation. Yolk sac is seen.

Fetal limb buds, stomach bubble, Falx seen. Cord insertion is normal.

Placenta : Forming along fundal wall. Not low lying.

Liquor : Adequate.

Fetal activity : Fetal activity present.

Cardiac activity : Cardiac activity present. FHR- 162 Bpm.

B/L Ovaries : Appears normal. No adnexal mass seen.

Biometry (Headlock):

❖ Crown Rump length measures 6.07 cm corresponding to 12 Weeks 4 Days.

NT SCAN:

❖ Nuchal translucency measures 1.6 mm - Normal for gestational age.

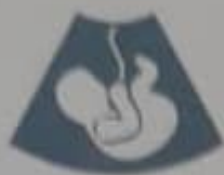❖ Nasal bone – Present.

❖ Ductus venosus shows normal waveform with no "a" wave reversal.

❖ No e/o tricuspid regurgitation.

रिशिकृपा

गेनाफी अँड डायग्नोस्टिक सेंटर



डॉ. ऋषिकान्त रमेश काटे

M.B.B.S. DMRE (CONSULTING RADIOLOGIST)

Reg No. 2015/06/3597

FETAL MEDICINE FOUNDATION (UK)

FMF ID: 240686

२ काटे पाटील टॉवर, जिजाऊ चौक, इंदूरप्रस्थ हॉटेलच्या बाजूला, मेन रोड, मेहकार ☎ 7499805785

Name: Mrs. PRATIKSHA RAVI PURANKAR
Age: 25 Years
Sex: Female

Ref By: Dr. SHUBHANGI R CHHALE Mom
Study: OBSTETRICS Visit No. 1
Date: 05-Nov-2025

EARLY OBSTETRIC ULTRASOUND EXAMINATION(TVS)

The real time, B mode, Gray scale sonography of gravid uterus was performed trans-Vaginally using a pure wave technology by GE Volusion S-8 BT-18 machine.

Visualisation: Good.Route:- Transvaginal.

LMP: 18/09/2025.

EDD by dates: 25/06/2026.

Indication-To diagnose intra-uterine and/or ectopic pregnancy and confirm viability.Estimation of gestational age (dating).

GESTATIONAL AGE:6 weeks 1 day from Gestational sac EDD by this scan: 30/06/2026.

MATERNAL:

- Internal os is closed. • Cervical length= 3.6 cm.
- No obvious corpus luteal cyst on either side.
- Right Adnexa: appears normal. • Left Adnexa: appears normal.

OBSTETRICS FINDINGS:

- Gravid anteverted uterus shows presence of an intrauterine gestational sac with no foetal pole appreciated.
- Foetal pole is not appreciated.
- Average gestational sac diameter is 1.26 cm = 6 weeks 1 day.
- Yolk sac is seen.

IMPRESSION:

- A single intrauterine gestational sac corresponding to 6 weeks 1 day with no foetal pole appreciated at present follow up after 2 weeks for viability.

SUGGEST:Follow up scan is recommended after 2 weeks for foetal pole and viability.

Photos with declaration form enclosed.

DECLARATION I Dr. RISHIKANT KATE declare that while conducting ultrasonography/image scanning etc. on this patient, I have neither detected nor disclosed sex of her fetus to anybody in any manner.



Dr. RISHIKANT KATE
M.B.B.S. DMRE (Radiologist)
Reg No-2015/06/3597.
Fetal Medicine Foundation(UK)
FMF ID - 240686

नॉंदणी कस्तुर घावी
is Advised For
Registration

