

Dhanashis Chavane

Emp - 26 Oct 2025

DOB - 23/05/2005

Height - 5 ft 6 inch

Weight - 60 kg

mob - 9595592949



समर्पणा

इमेजिंग (सोनोग्राफी) सेंटर, वार्शी
Diagnosis with Care and Excellence

डॉ. मनोज बी. जाधव

MBBS(JJH), MD (RAD), DNB, MNAMS, DICR, EDIR
FFM (Fellowship in Fetal Medicine), Bangalore
Ex. Senior Resident Sion Hospital, Mumbai
Ex. Clinical Associate, Apollo Hospital, Navi Mumbai
Consultant Radiologist
Fetomaternal Imaging Consultant
FMF Certified (11-13 wks Scan)



PATIENT NAME	: Mrs. DHANSHREE SHARAD GAVHANE	AGE/SEX	: 20 Years/ F
REF. BY	: Dr. SADEKAR SHIVAJI, MBBS, MS (OB/GY)	DATE	: 21-Jan-26

OB-First Trimester Scan Report

LMP: 26-Oct-25	GA (LMP): 12 weeks 3 days	EDD (LMP): 02-Aug-26
----------------	---------------------------	----------------------

Real time B-mode ultrasonography of gravid uterus done.

Route: Transabdominal

Maternal:

Cervix measured 3.17 cm in length. OS closed.

Right uterine PI : 1.00

Left uterine PI : 0.89

Mean PI : 0.95 (1 %)

Fetus Survey

: Single intrauterine gestation.

Placenta : Anterior wall, covering internal OS.

Liquor : Normal.

Umbilical cord : Three vessel cord seen.

Fetal activity : Fetal activity present.

Cardiac activity : Cardiac activity present. Fetal heart rate-184 bpm

Biometry (Headlock)

	Measurement	GA	Percentile	Graph
BPD	1.67 cm	12 weeks 3 days	22.30 %	
HC	6.82 cm	12 weeks 5 days	27.40 %	
AC	5.46 cm	12 weeks 3 days	58.60 %	
FL	0.79 cm	12 weeks 3 days	39.30 %	
EFW	58 gms	12 weeks 0 days	22.40 %	

CRL- 5.06 cm. (11 weeks 6 days) IT (Intracranial translucency) – 0.11 cm

Aneuploidy Markers

Nasal Bone : 0.16 cm -Present

Nuchal translucency : 0.11 cm -Normal.

Ductus venosus : No "a" wave reversal.

Tricuspid regurgitation : No tricuspid regurgitation seen.

Fetal anatomy:

Head : Skull/brain appears normal. Intracranial structures appear normal.

Neck : Neck appears normal.

Spine : Spine appears normal.

Face : PMT and orbits seen.

Thorax : Thorax appears normal.

Heart : Four chamber and outflow tracts appear normal.

Abdomen : Stomach bubble appears normal. Cord insertion seen.

KUB : Bladder appears normal. Kidneys could not be evaluated at present.

Extremities : Both upper limbs and lower limbs seen.

P.T.O.

Dr. Manoj B. Jadhav

Reg. No. 2013/07/2596

71004 48919



समर्पण

इमेजिंग (सोनोग्राफी) सेंटर, बारशी
Diagnosis with Care and Excellence

डॉ. मनोज बी. जाधव

MBBS(JJH), MD (RAD), DNB, MNAMS, DICR, EDiR
FFM (Fellowship in Fetal Medicine), Bangalore
Ex. Senior Resident Sion Hospital, Mumbai
Ex. Clinical Associate, Apollo Hospital, Navi Mumbai
Consultant Radiologist
Fetomaternal Imaging Consultant
FMF Certified (11-13 wks Scan)



PATIENT NAME	: Mrs. DHANSHREE SHARAD GAVHANE	AGE/SEX	: 20 Years/ F
REF. BY	: Dr. SADEKAR SHIVAJI, MBBS, MS (OB/GY)	DATE	: 21-Jan-26

IMPRESSION:

- Single live intrauterine gestation corresponding to gestational age of 11 weeks 6 days.
- Menstrual age is 12 weeks 3 days.
- EDD by USG (Biometry-CRL): 06-Aug-26.
- Assigned EDD (As per LMP): 02-Aug-26.
- Nuchal translucency (0.11 cm), nasal bone, tricuspid regurgitation: within normal limits.
- Endocervical length: 3.17 cm: Normal however it will be best assessed after 14 weeks.
- Uterine artery screen negative for PET.
- No obvious sonological structural abnormalities detected for this gestation.

COMMENTS:

First Trimester Screening for Trisomies:

Risks from History

Trisomy 21: 1 in 950

Trisomy 13/18: 1 in 1600

The risk from history is based on a maternal age of 20 years and previous affected pregnancies.

Risks from History, NT

Trisomy 21: 1 in 8600

Trisomy 13/18: 1 in 5800

The adjusted risk is the risk at the time of screening. The calculation is based on the background risk and the following parameters: Ultrasound factors (NT).

SUGGEST:

1) Double marker test today.

2) TIFFA (level II) scan between 18-20 weeks.

Thanks for the reference,
With regards.

Please Note: All abnormalities and genetic syndromes cannot be ruled out by ultrasound examination. Ultrasound examination has its own limitations. Some abnormalities evolve as the gestation advances. The pickup rate of abnormality depends on gestational age of the fetus, fetal position, tissue penetration of sound waves, and patient's body habitus.

Disclaimer: I Dr. Manoj B. Jadhav declare that while conducting ultrasonography/image scanning on this patient, have neither detected nor disclosed the sex of her fetus to anybody in any manner.

Best Wishes,
For Appointments Please Contact: 7498648919.


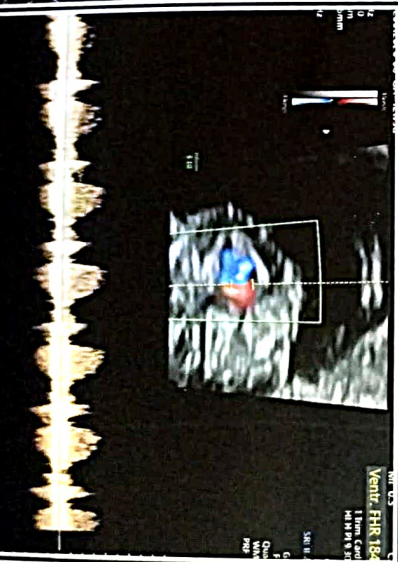
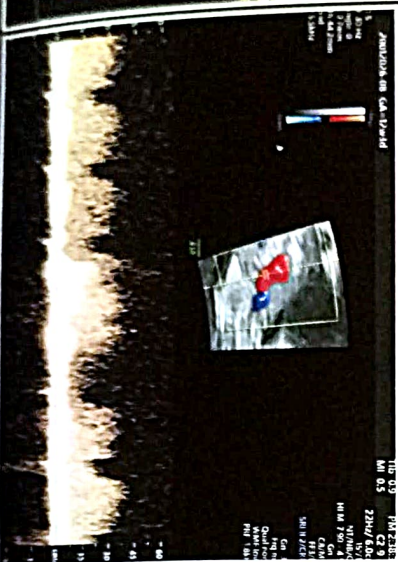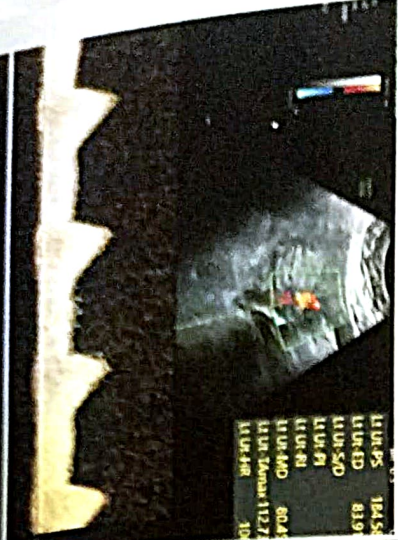
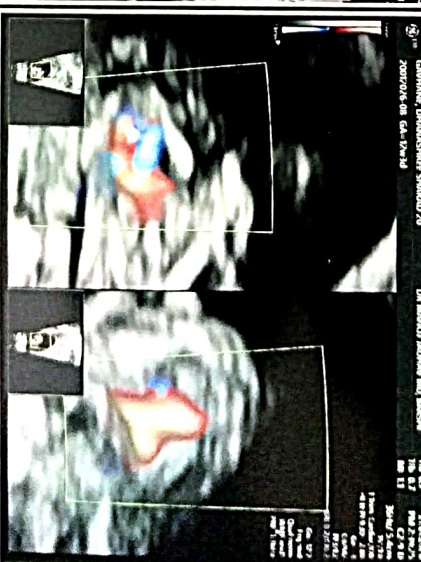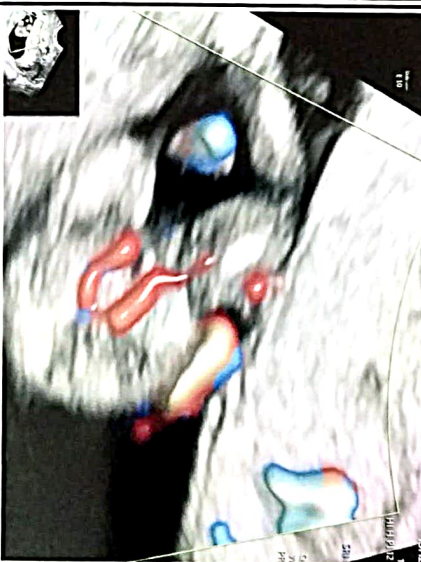
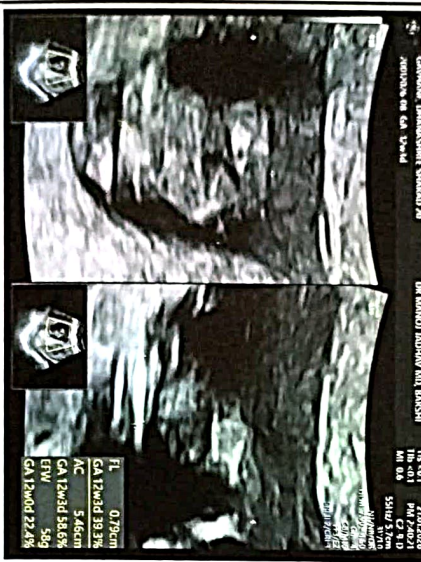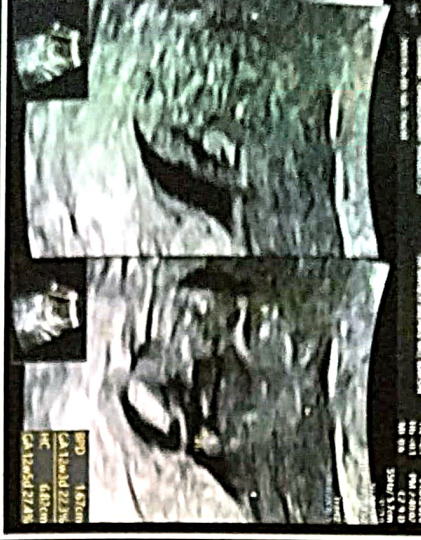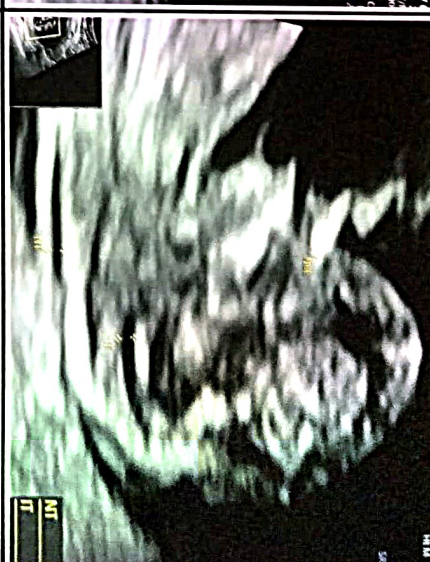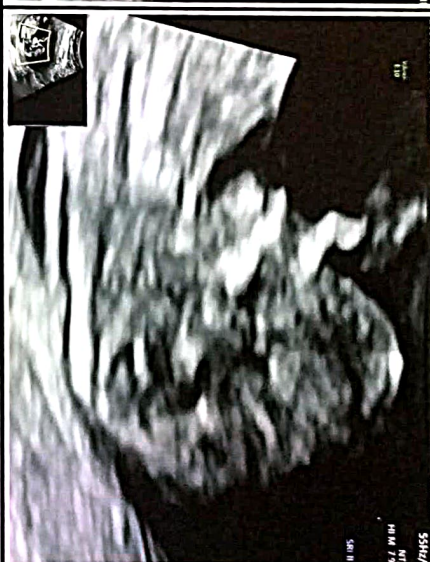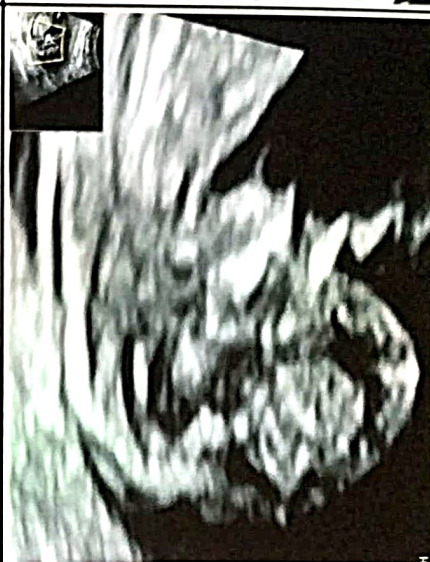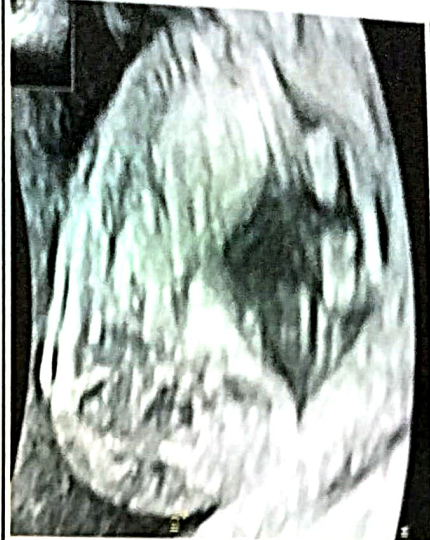Dr. Manoj B. Jadhav

Reg. No. 2013/07/2596

SAMARPAN DIAGNOSTIC CENTER, BARSHI

Name : GAYANE DHANASHREE SHARAD / F

21 Jan 2026



GAUTAM DHANASHREE SHARAD 20
20/01/2026
CA 12M03 38.3K
ETW 386
CA 12M03 32.4K

GAUTAM DHANASHREE SHARAD 20
20/01/2026
CA 12M03 38.3K
ETW 386
CA 12M03 32.4K

GAUTAM DHANASHREE SHARAD 20
20/01/2026
CA 12M03 38.3K
ETW 386
CA 12M03 32.4K

GAUTAM DHANASHREE SHARAD 20
20/01/2026
CA 12M03 38.3K
ETW 386
CA 12M03 32.4K

GAUTAM DHANASHREE SHARAD 20
20/01/2026
CA 12M03 38.3K
ETW 386
CA 12M03 32.4K

GAUTAM DHANASHREE SHARAD 20
20/01/2026
CA 12M03 38.3K
ETW 386
CA 12M03 32.4K

GAUTAM DHANASHREE SHARAD 20
20/01/2026
CA 12M03 38.3K
ETW 386
CA 12M03 32.4K

GAUTAM DHANASHREE SHARAD 20
20/01/2026
CA 12M03 38.3K
ETW 386
CA 12M03 32.4K

GAUTAM DHANASHREE SHARAD 20
20/01/2026
CA 12M03 38.3K
ETW 386
CA 12M03 32.4K